

THE STATE OF THE CARDIOVASCULAR SYSTEM IN NORMAL AND OBESE PONIES ACCORDING TO THE RESULTS OF CARDIOGRAPHIC STUDIES

Borovkov S. B. ¹, Borovkova V. M. ²

¹ National Scientific Center 'Institute of Experimental and Clinical Veterinary Medicine', Kharkiv, Ukraine, e-mail: serg_b78@ukr.net

² State Biotechnological University, Kharkiv, Ukraine

Summary. Horses and ponies have physiological peculiarities in their cardiovascular system in comparison with other species as well as among themselves. Electrocardiogram (ECG) studies in ponies help to elucidate the peculiarities of cardiovascular system functioning, to establish reference values for parameters and to perform early diagnosis of arrhythmias. Arrhythmias, or irregular heart rhythms, can significantly affect the health of horses. Regular ECG screening can help detect early signs of cardiovascular disease such as myocarditis, valvular disease and congenital heart defects. Since horses and ponies come in different breeds, each with unique cardiovascular characteristics, this study aims to establish normative electrocardiogram parameters for ponies to allow for more accurate interpretation of electrocardiographic data. The study involved 18 ponies, aged 4–9 years, in a relatively calm state. Nine animals formed the control group and nine with signs of obesity formed the study group. All animals underwent a general clinical examination using widely accepted methods. Electrocardiographic studies were performed using the BeeW recorder, a state-of-the-art miniature electrocardiograph that allows registration, analysis and interpretation of electrocardiograms over the Internet using an Android tablet, smartphone or laptop. The study showed that the average heart rate (HR) for all ponies was 44.6 ± 2.1 bpm. No cases of sinus bradycardia with HR below 24 bpm were observed. Thirteen animals (72.2%) had HR in the range of 24–42 bpm, while five animals (27.8%) had sinus tachycardia. ECG findings showed positive P waves in 10 animals (55.5%) and negative P waves in 8 (44.5%). Positive T waves were observed in 5 animals (27.8%), while 13 (72.2%) had negative T waves. The QRS complex was predominantly a qR pattern with variations including QR, Qr, and qRS. In addition, two animals had sinus tachycardia and two had atrioventricular block

Keywords: arrhythmia, sinus tachycardia, atrioventricular block

Introduction. Currently, ponies are of interest as companion animals that can improve the emotional and psychological state of people. However, information on the normative indicators of electrocardiographic studies in ponies in normal and pathologies of the cardiovascular system is practically absent in the domestic scientific literature (Maksimovich, 2014, 2016). In the publications of foreign researchers there are reports of electrocardiographic studies in small breeds of horses, including ponies (Van Vollenhoven et al., 2016; Paslawska et al., 2018; Durham, 2017). These studies have established that horses and their varieties of ponies have anatomical and physiological differences, therefore the use of clinical data, treatments and diagnostic protocols from horses to ponies can cause diagnostic errors and inappropriate therapeutic intervention (Pedersen et al., 2016; Santarosa et al., 2016). Clinical signs of cardiovascular disease, or their absence, are important factors in assessing the possible health status of animals, but given the considerable compensatory capacity of the equine heart, clinical signs are only manifested in cases of severe cardiac dysfunction or during intense exercise. It should also be noted that the sounds and arrhythmias commonly heard in horses are often of physiological origin and have no pathological significance. Arrhythmias during or immediately after exercise are common in sport horses (Mathapati and Saini, 2019).

Digital telemetry electrocardiogram recording systems are lightweight and portable and can be used to obtain real-time digital monitoring and recording at rest or during exercise (Piketh, 2019; Houben, Vernooij and Sloet Van Oldruitenborgh-Oosterbaan, 2021). There is little information in the literature on the normative indicators of electrocardiograms in ponies, as well as the presence of arrhythmias of different types.

Therefore, the **aim of the study** was to establish normal electrocardiographic parameters in normal and obese ponies and to illustrate electrocardiographic parameters at rest and with some types of arrhythmias.

Materials and methods. The ponies kept in the Regional Landscape Park 'Feldman Ecopark' (Lisne, Kharkiv District, Kharkiv Region) were studied, namely 18 ponies, male and female, aged 4–9 years, in a state of relative rest. The research was carried out in 2018.

All animals underwent a general clinical examination according to generally accepted methods. Electrocardiographic studies were performed using the BeeW recorder, a state-of-the-art miniature electrocardiograph that allows recording, analysis, and interpretation of electrocardiograms via the Internet using an Android tablet, smartphone, or laptop. It is a professional quality electrocardiograph. Its main parameters meet international requirements (bandwidth, time constant, etc.). Variant of the BeeW recorder: 4-wire

6-channel. The electrodes were attached to the skin with alligator clips, the skin was previously moistened with alcohol. Recordings were made by placing the electrodes according to Domrachev–Vaskanian: red — in the area of the elbow tubercle of the left forelimb, yellow — in the elbow tubercle of the right forelimb, green — in the area of the right knee crease, black — in the left knee crease. For each electrocardiographic recording, heart rate, rhythm, P wave duration and amplitude, PR interval duration, QRS complex duration, R wave amplitude, S wave amplitude, QT interval and QTc duration, and T wave duration and amplitude were analyzed.

During the experimental studies described in this work, all manipulations with ponies involved in the research were conducted following the recommendations of the 'European Convention for the Protection of Vertebrate Animals Used for Experimental and Other Scientific Purposes' (CE, 1986) and Council Directive 2010/63/EU (CEC, 2010), and in accordance with Art. 26 of the Law of Ukraine No. 3447-IV of 21.02.2006 'About protection of animals from cruel treatment' (VRU, 2006) and basic bioethical principles (Simmonds, 2017).

Statistical analysis of the data was performed using the Microsoft Excel analysis package.

Results and discussion. The mean heart rate for 18 ponies was 44.6 ± 2.1 bpm. Accordingly, no animal had manifestations of sinus bradycardia and a heart rate below 24 bpm, 13 animals (72.2%) had a heart rate in the

range of 24–42 bpm, and five animals (27.8%) had sinus tachycardia. In addition, the heart rate in obese horses was significantly higher than in clinically healthy ponies, 48.6 ± 2.6 bpm versus 39.2 ± 1.9 bpm ($p < 0.01$). The average heart rate found in our study is higher than that of horses, suggesting that there are differences in autonomic nervous system activity between ponies and horses. Heart rate variability can be used to diagnose the autonomic nervous system and assess the cardiovascular system.

According to Mitchell and Schwarzwald (2021) and Lorello et al. (2019), a regular sinus rhythm with a resting heart rate of 24 to 44 bpm is the most common rhythm found in horses. Adult, physically fit horses are known to have high vagal tone at rest, resulting in a low heart rate. According to Cruz-Aleixo et al. (2023) and Decloedt et al. (2021), and our studies, the average heart rate in ponies is slightly higher than in horses, suggesting that equine reference values should not be used to assess parameters in ponies.

For a complete assessment of the electrocardiogram, it is important to evaluate the waves and intervals. Thus, according to the results of the study in ponies, positive P waves were observed in 10 animals (55.5%), negative in 8 animals (44.5%), positive T waves in 5 animals (27.8%), negative in 13 animals (72.2%). The electrocardiogram showed a predominance of the QRS complex form of the qR type, but other variants were also observed, such as QR, Qr, qRS (Fig. 1).

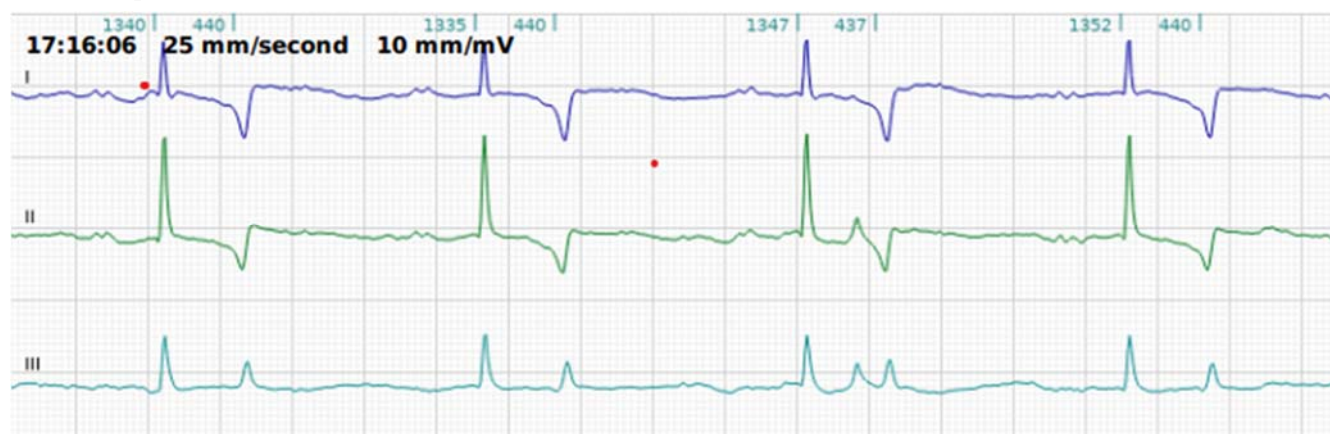


Figure 1. Electrocardiogram of a pony, 6 years old, type qR and bifurcated P waves.

In most of the animals, a split wave P was recorded, similar to that recorded in the studies of other authors. In addition, according to Chope (2018) and Navas De Solis et al. (2014), a QRS complex of the rS type is recorded in ponies, which is different from our studies. We believe that these differences may be related to different breeds and possibly the sex of the pony, as the authors mention that they found the QS pattern only in females (Tzelos, Blissitt and Clutton, 2015; Zuber, Zuber and Schwarzwald, 2019). It should be noted that the directionality of the teeth was not significantly different

between clinically healthy and obese ponies (Fig. 2). Weis et al. (2022) and Van Loon (2019a, 2019b) also found certain types of physiological arrhythmias on the ECG. These include second-degree atrioventricular block and sinus arrhythmias. The true prevalence and frequency of these arrhythmias is likely underestimated in this study because the recordings were short and the use of an ECG and the presence of a physician can alter autonomic tone (Hanka, Van Den Hoven and Schwarz, 2015; Van Loon, 2019a, 2019b). For a complete assessment of heart rate in horses and ponies, researchers suggest performing daily

ECG recordings using Holter monitoring (Sebdani et al., 2019; Vezzosi et al., 2019), which may be the prospect of further research. The Fig. 3 shows atrioventricular

block II in a non-obese pony. It should be noted that in the group of obese horses, one case of this block was also recorded (Heliczner et al., 2017; McDuffee et al., 2019).

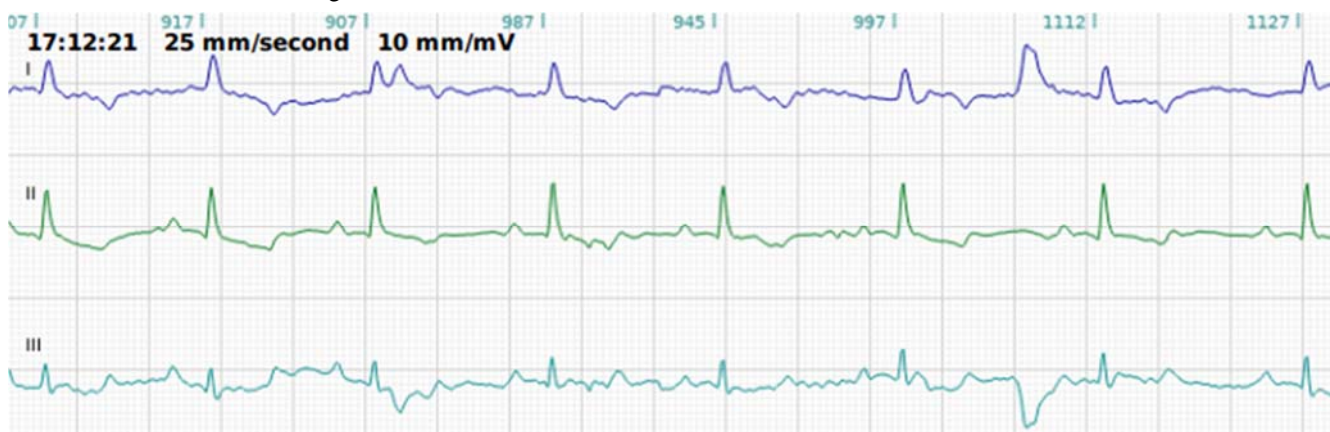


Figure 2. Electrocardiogram of an 8-year-old pony with sinus tachycardia due to obesity.

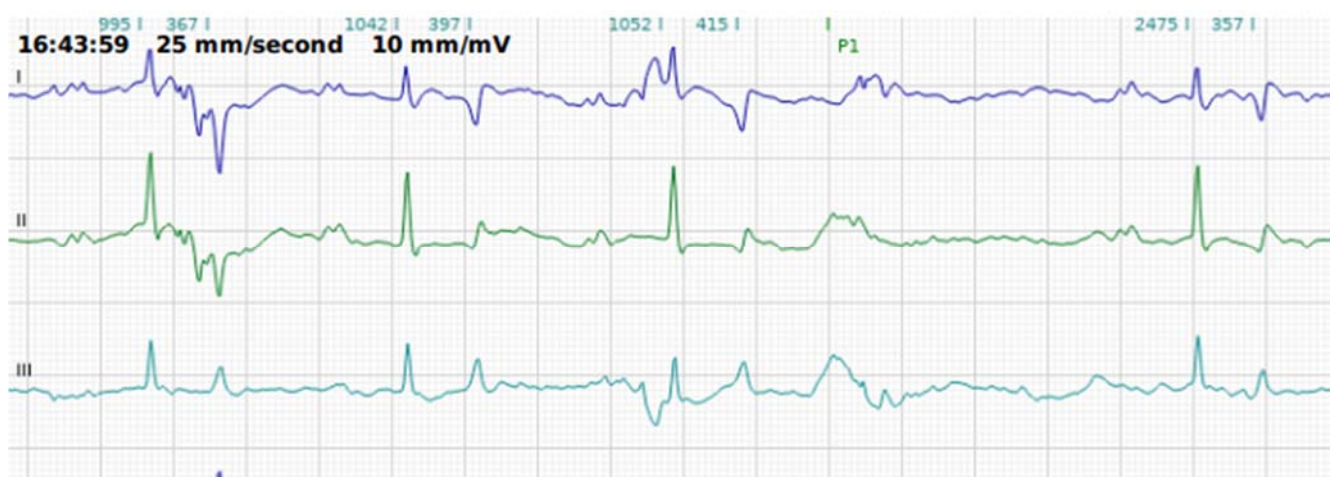


Figure 3. Electrocardiogram of a non-obese pony, 7 years old, with degree II atrioventricular block.

Conclusions. The average heart rate (HR) for all ponies was 44.6 ± 2.1 bpm. No cases of sinus bradycardia with HR below 24 bpm were observed. Thirteen animals (72.2%) had HR in the range of 24–42 bpm, while five animals (27.8%) had sinus tachycardia. ECG findings showed positive P waves in 10 animals (55.5%) and negative P waves in 8 (44.5%). Positive T waves were observed in 5 animals (27.8%), while 13 (72.2%) had

negative T waves. The QRS complex was predominantly a qR pattern with variations including QR, Qr, and qRS. In addition, two animals had sinus tachycardia and two had atrioventricular block.

Electrocardiogram is an affordable and informative method to assess the state of cardiovascular system in horses and ponies in normal and pathological conditions.

References

- CE (The Council of Europe). (1986) *European Convention for the Protection of Vertebrate Animals Used for Experimental and Other Scientific Purposes*. (European Treaty Series, No. 123). Strasbourg: The Council of Europe. Available at: <https://conventions.coe.int/treaty/en/treaties/html/123.htm>.
- CEC (The Council of the European Communities) (2010) 'Directive 2010/63/EU of the European Parliament and of the Council of 22 September 2010 on the protection of animals used for scientific purposes', *The Official Journal of the European Communities*, L 276, pp. 33–79. Available at: <http://data.europa.eu/eli/dir/2010/63/oj>.
- Chope, K. B. (2018) 'Cardiac/cardiovascular conditions affecting sport horses', *Veterinary Clinics: Equine Practice*, 34(2), pp. 409–425. doi: 10.1016/j.cveq.2018.04.001
- Cruz-Aleixo, A. S., De Oliveira, K. C., De Oliveira Ferreira, L. V., Cedeo Quevedo, D. A., Cruz, R. K. S., Tsunemi, M. H., Chiacchio, S. B. and Lourenço, M. L. G. (2023) 'Electrocardiographic and echocardiographic parameters in Pega breed donkeys: A descriptive study', *Animals*, 13(5), p. 861. doi: 10.3390/ani13050861.
- Declodt, A., Van Steenkiste, G., Vera, L., Buhl, R. and Van Loon, G. (2021) 'Atrial fibrillation in horses. Part 2: Diagnosis, treatment and prognosis', *The Veterinary Journal*, 268, p. 105594. doi: 10.1016/j.tvjl.2020.105594.

- Durham, H. E. (2017) 'Equine Cardiology', in Durham, H. E. (ed.) *Cardiology for Veterinary Technicians and Nurses*. Wiley, pp. 405–441. doi: 10.1002/9781119357407.ch17.
- Hanka, J., Van Den Hoven, R. and Schwarz, B. (2015) 'Paroxysmales Vorhofflimmern und klinisch reversibles Cor pulmonale bei einem Pferd mit komplizierter rezidivierender Atemwegsobstruktion', *Tierärztliche Praxis Ausgabe G: Großtiere / Nutztiere*, 43(02), pp. 109–114. doi: 10.15653/TPG-140075.
- Heliczner, N., Gerber, V., Bruckmaier, R., Van Der Kolk, J. H. and De Solis, C. N. (2017) 'Cardiovascular findings in ponies with equine metabolic syndrome', *Journal of the American Veterinary Medical Association*, 250(9), pp. 1027–1035. doi: 10.2460/javma.250.9.1027.
- Houben, R. M. A. C., Vernooij, H. J. C. M. and Sloet Van Oldruitenborgh-Oosterbaan, M. M. (2021) 'Effect of recording length and posture on the reliability of heart rate variability in horses', *Pferdeheilkunde Equine Medicine*, 37(6), pp. 577–587. doi: 10.21836/PEM20210603.
- Lorello, O., Ramseyer, A., Burger, D., Gerber, V. and Navas De Solis, C. (2019) 'Cardiovascular variables in eventing and endurance horses over a season', *Journal of Veterinary Cardiology*, 21, pp. 67–78. doi: 10.1016/j.jvc.2018.08.004.
- Maksimovich, I. A. (2014) 'Cardiac arrhythmias in horses: distribution, etiology and diagnosis [Aritmii serdtsa v loshadey: rasprostranenie, etiologiya i diagnostika]', *Scientific Messenger of Lviv National University of Veterinary Medicine and Biotechnologies named after S. Z. Gzhytskyj [Naukovyi visnyk Livskoho natsionalnoho universytetu veterynarnoi medytsyny ta biotekhnolohii imeni S. Z. Gzhytskoho]*, 16(2.1), pp. 205–214. Available at: [http://nbuv.gov.ua/UJRN/nvlnu_2014_16_2\(1\)_29](http://nbuv.gov.ua/UJRN/nvlnu_2014_16_2(1)_29). [in Ukrainian].
- Maksimovich, I. A. (2016) 'Prevalence and diagnosis of cardiac arrhythmias in sports horses [Poshyrennia ta diahnostryka sertsevykh arytymii u sportyvnykh konei]', *Scientific Bulletin of Veterinary Medicine [Naukovyi visnyk veterynarnoi medytsyny]*, 2, pp. 57–63. Available at: http://nbuv.gov.ua/UJRN/nvnm_2016_2_12. [in Ukrainian].
- Mathapati, P. V. and Saini N. (2019) 'Holter monitoring electrocardiography in thoroughbred horses at rest and during exercise', *Intas Polivet*, 20(2), pp. 216–219. Available at: <https://www.indianjournals.com/ijor.aspx?target=ijor:ipo&volume=20&issue=2&article=002>.
- McDuffee, L., Mills, M., McNiven, M. and Montelpare, W. (2019) 'Establishing statistical stability for heart rate variability in horses', *Journal of Veterinary Behavior*, 32, pp. 30–35. doi: 10.1016/j.jveb.2019.05.003.
- Mitchell, K. J. and Schwarzwald, C. (2021) 'Heart rate variability analysis in horses for the diagnosis of arrhythmias', *The Veterinary Journal*, 268, 105590. doi: 10.1016/j.tvjl.2020.105590.
- Navas De Solis, C., Green, C. M., Sides, R. H. and Bayly, W. M. (2016) 'Arrhythmias in thoroughbreds during and after treadmill and racetrack exercise', *Journal of Equine Veterinary Science*, 42, pp. 19–24. doi: 10.1016/j.jevs.2016.03.018.
- Pasławska, U., Michlik, K., Janus, I., Pasławski, R., Zyśko, D. and Noszczyk-Nowak, A. (2018) 'Physiological values of ECG parameters in Silesian horses', *Medycyna Weterynaryjna*, 74(9), pp. 577–580. doi: 10.21521/mw.5972.
- Pedersen, P. J., Karlsson, M., Flethoj, M., Trachsel, D. S., Kanters, J. K., Klærke, D. A. and Buhl, R. (2016) 'Differences in the electrocardiographic QT interval of various breeds of athletic horses during rest and exercise', *Journal of Veterinary Cardiology*, 18(3), pp. 255–264. doi: 10.1016/j.jvc.2016.02.002.
- Piketh, G. (2019) *Application of a Smartphone Modulated ECG Device for Use in Equines*. Thesis submitted in partial fulfilment of the requirements for the degree Master of Science. Pretoria, South Africa: University of Pretoria. Available at: <http://hdl.handle.net/2263/76762>
- Santarosa, B. P., Lourenço, M. L. G., Dantas, G. N., Ulian, C. M. V., Heckler, M. C. T., Sudano, M. J., Gonçalves, R. C. and Chiacchio, S. B. (2016) 'Electrocardiographic parameters of the American miniature horse: influence of age and sex', *Pesquisa Veterinária Brasileira*, 36(6), pp. 551–558. doi: 10.1590/S0100-736X2016000600015.
- Sebdani, M. M., Rezakhani, A., Pourjafar, M. and Chalmeh, A. (2019) 'The comparative practical efficiency of short-term electrocardiography and 24-hour Holter monitoring for evaluating the cardiac electrical activity of horses', *Veterinarski Arhiv*, 89(3), pp. 267–277. Available at: <https://hrcak.srce.hr/222684>.
- Simmonds, R. C. (2017) 'Chapter 4. Bioethics and animal use in programs of research, teaching, and testing', in Weichbrod, R. H., Thompson, G. A. and Norton, J. N. (eds.) *Management of Animal Care and Use Programs in Research, Education, and Testing*. 2nd ed. Boca Raton: CRC Press, pp. 35–62. doi: 10.1201/9781315152189-4.
- Tzelos, T., Blissitt, K. J. and Clutton, R. E. (2015) 'Electrocardiographic indicators of excitability in horses for predicting recovery quality after general anaesthesia', *Veterinary Anaesthesia and Analgesia*, 42(3), pp. 269–279. doi: 10.1111/vaa.12199
- Van Loon, G. (2019a) 'Cardiac arrhythmias in horses', *Veterinary Clinics of North America: Equine Practice*, 35(1), pp. 85–102. doi: 10.1016/j.cveq.2018.12.004.
- Van Loon, G. (2019b) 'Clinical relevance of heart arrhythmias', *XXIII Tagung über Pferdekrankeheiten*, Essen, 15–16 März, 2019, pp. 24–27. Available at: <https://core.ac.uk/download/pdf/286086631.pdf>.
- Van Vollenhoven, E., Grant, C. C., Fletcher, L., Ganswindt, A. and Page, P. C. (2016) 'Repeatability and reliability of heart rate variability in healthy, adult pony mares', *Journal of Equine Veterinary Science*, 46, pp. 73–81. doi: 10.1016/j.jevs.2016.07.006.
- Vezzosi, T., Vitale, V., Sgorbini, M., Tognetti, R. and Bonelli, F. (2019) 'Two methods for 24-hour Holter monitoring in horses: Evaluation of recording performance at rest and during exercise', *Journal of Equine Veterinary Science*, 79, pp. 127–130. doi: 10.1016/j.jevs.2019.06.001.
- VRU (Verkhovna Rada Ukrainy) (2006) 'Law of Ukraine No. 3447-IV of 21.02.2006 'About protection of animals from cruel treatment' [Zakon Ukrainy № 3447-IV vid 21.02.2006 'Pro zakhyt tvaryn vid zhorstokoho povodzhennia', *News of the Verkhovna Rada of Ukraine [Vidomosti Verkhovnoi Rady Ukrainy]*, 27, art. 230. Available at: <https://zakon.rada.gov.ua/laws/3447-15>. [in Ukrainian].
- Weis, R., Carstensen, H., Sattler, S. M., Buhl, R. and Hesselkilde, E. M. (2022) 'Electrocardiographic changes in a horse with induced myocardial infarction', *Animals*, 12(10), pp. 1272. doi: 10.3390/ani12101272.
- Zuber, N., Zuber, M. and Schwarzwald, C. C. (2019) 'Assessment of systolic and diastolic function in clinically healthy horses using ambulatory acoustic cardiography', *Equine Veterinary Journal*, 51(3), pp. 391–400. doi: 10.1111/evj.13014.