

# Part 1. Veterinary medicine

UDC 619:617.5-089.443:615.454.1:636.7/.8

DOI 10.36016/JVMBBS-2026-12-1-1

## CLINICAL MANAGEMENT OF WOUNDS IN DOGS AND CATS WITH VARIOUS NOSOLOGICAL PROFILES USING HYDROGEL APPLICATIONS

Kazantsev R. H. <sup>1</sup>, Kryvoruchenko D. O. <sup>2</sup>, Slyusarenko D. V. <sup>2</sup>, Zaika P. O. <sup>2</sup>, Syniahovska K. A. <sup>2</sup><sup>1</sup> National Scientific Center 'Institute of Experimental and Clinical Veterinary Medicine', Kharkiv, Ukraine, e-mail: [trilobite@ukr.net](mailto:trilobite@ukr.net)<sup>2</sup> State Biotechnological University, Kharkiv, Ukraine

**Summary.** The article analyzes the peculiarities of the wound-healing process in dogs and cats with tissue defects that healed by secondary tension. The study was conducted on 34 animals at a private veterinary clinic and involved 60 days of prospective observation. The etiological structure of the wounds was determined, revealing that bite injuries dominated. The study demonstrated the dependence of the topographic localization of wounds on the type of animal, with predominant damage to the limbs and cervical region. The focus is on the peculiarities of the regeneration process during secondary healing, particularly hemostasis, inflammation, proliferation, and remodeling. It has been confirmed that the duration of the wound healing process is independent of animal species, breed, sex, or injury location. The decisive role of tissue deficit volume and complicating medical history in regeneration dynamics is emphasized. The feasibility of using hydrogel applications in the complex treatment of wounds of various etiologies that heal by secondary intention is supported. Experimental studies have proven that hydrogels promote wound cleansing, maintain optimal moisture levels, and stimulate granulation tissue. These results confirm the effectiveness of a comprehensive approach to treating purulent and complicated wounds in small domestic animals, and they can be applied in the field of practical veterinary medicine

**Keywords:** diagnosis, assessment, body injuries, sharp objects, healing, scars, animals

**Introduction.** In veterinary practice, wounds are one of the most common pathologies. Their timely and adequate treatment is essential to maintaining the quality of life of animals (Wilkinson and Hardman, 2020). The wound healing process is complex and dynamic, ensured by closely coordinated cellular, molecular, and tissue interactions. Any traumatic injury triggers an inflammatory response, leading to excessive production of inflammatory mediators and the activation or recruitment of immune cells. Under certain conditions, this can lead to a systemic inflammatory response in the body (Yu et al., 2015).

Depending on their origin, wounds are classified as traumatic, surgical, or burn wounds. Traumatic wounds result from mechanical damage, such as cuts, bites, or blows. They are often accompanied by significant soft tissue damage and microbial contamination (Gillespie et al., 2020). Surgical wounds result from surgical interventions and are usually controlled. However, an increased number of operations on patients with comorbidities increases the risk of surgical site infection and wound complications (Cochetti et al., 2020). Burn wounds are caused by high temperatures, chemicals, electric currents, or radiation, and they can vary in depth and extent of damage (Jeschke et al., 2020). Severe burn injuries lead to significant immune, inflammatory, and metabolic disruptions. These injuries can lead to multiple organ dysfunction and have a long-term negative impact

on patients' physical and psychoemotional states (Jeschke et al., 2020).

Depending on the nature of the injury, wounds are classified as superficial, deep, or penetrating. Superficial wounds only affect the epidermis and usually heal without complications. Deep wounds penetrate the dermis and subcutaneous tissue, requiring longer treatment. Penetrating wounds are characterized by damage to internal organs or cavities, posing an immediate threat to the animal's life. Depending on the degree of contamination, wounds are classified as clean, contaminated, or infected. This classification is important for choosing a treatment strategy. Wounds are classified as acute or chronic based on healing time. Acute wounds usually heal within two to three weeks, while chronic wounds do not show a tendency to heal within three weeks and often recur. Chronic wounds pose a significant biological and socioeconomic burden. Their pathogenesis is associated with pathologically prolonged inflammation, hypoxia, ischemic-reperfusion injury, and bacterial colonization (Zhao et al., 2016).

Wound healing occurs in successive, partially overlapping phases. Disruption of any phase can lead to chronicity or excessive scarring (Fernández-Guarino et al., 2023). Excessive scar tissue formation leads to hypertrophic scars and keloids, which may be accompanied by pain, itching, and functional impairment (Martin and Nunan, 2015).

The classical model distinguishes four main phases of wound healing: hemostasis, inflammation, proliferation, and remodeling. The initial hemostatic phase is characterized by microvascular damage, fibrin clot formation, platelet aggregation, and fibroblast activation. Fibroblasts play a key role in subsequent tissue repair. The inflammatory phase involves the infiltration of neutrophils, monocytes, and lymphocytes into the wound, cleansing the wound defect and creating conditions for subsequent regeneration stages (Knoedler et al., 2023).

The proliferative phase is characterized by the formation of granulation tissue, active angiogenesis, migration, and proliferation of fibroblasts and epithelial cells. Granulation tissue consists of newly formed vessels and an extracellular matrix rich in collagen and other structural proteins. Cell adhesion to the extracellular matrix via integrin receptors is a prerequisite for cell cycle progression and effective tissue regeneration (Kamranvar, Rani and Johansson, 2022).

At the same time, epithelialization occurs, during which epithelial cells migrate from the edges of the wound and form a new epidermis, providing the skin with barrier, protective, and immune functions (De Szalay and Wertz, 2023). Myofibroblasts play an important role in wound contraction and scar tissue formation by synthesizing and organizing the extracellular matrix, restoring the mechanical integrity of tissues; however, their excessive or prolonged activity can lead to fibrosis (Schuster et al., 2022).

Exudation is an essential component of the wound healing process. Wound fluid, derived from blood plasma, contains oxygen, nutrients, cytokines, growth factors, and cellular elements necessary for cleansing and healing the wound (Saravi et al., 2023). However, excessive or prolonged exudation, especially if it is cloudy or purulent, indicates infection or necrotic tissue. In this case, more active surgical intervention and a correction to the treatment strategy are required (Beraja et al., 2025).

The type of wound treatment required depends on the stage of the wound healing process, the type of injury, and the patient's overall health. The main principles are: thorough cleansing of the wound; prevention or control of infection; maintenance of an optimal moist environment; and stimulation of tissue regeneration (Fani et al., 2024). Modern wound treatment approaches are based on using dressing materials that promote physiological healing. Moist-dry dressings, which were previously widely used, are no longer considered the standard of care due to their negative impact on tissue regeneration (Ousey et al., 2016).

Hydrogel dressings are becoming increasingly popular as they provide an optimal moist environment, reduce inflammatory reactions, and stimulate repair processes, particularly in chronic wounds (Huang et al., 2022). Calcium-based alginate dressings, polyurethane foam dressings, hydrocolloids, and hydrogels are among the most widely used modern wound dressings. Calcium

alginate is particularly effective for deep, exuding wounds and has a pronounced hemostatic effect (Zhang, Cheng and Ao, 2021). Hydrocolloid dressings create a moist environment and are typically used to treat chronic wounds and second-degree burns (Zaika et al., 2024). Polyurethane foam dressings are used for wounds with moderate to heavy exudation, providing mechanical protection and gas exchange (Holmes et al., 2022). Hydrogels, due to their high water content and biocompatibility, are promising materials for treating wounds during the granulation and epithelialization phases. Additionally, they can incorporate antibacterial components (Liu et al., 2022).

Thus, the above-discussed works indicate the relevance of wound treatment in veterinary medicine, given the high prevalence of wounds and the risk of complications. The introduction of biocompatible wound dressings — particularly hydrogel applications — is seen as a promising direction in modern practice, as they allow targeted influence on the course of the wound healing process and increase the effectiveness of therapy.

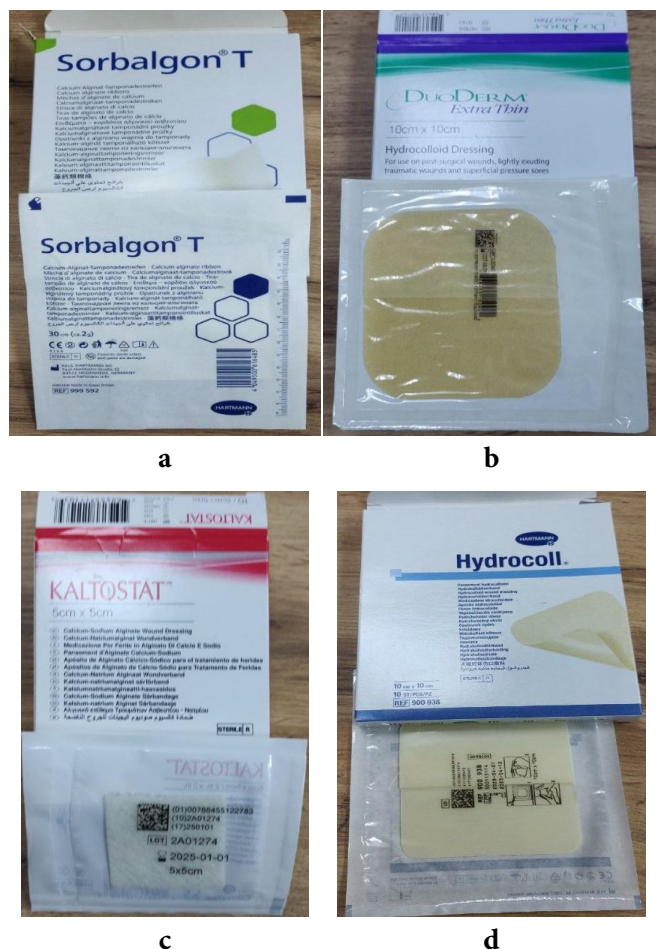The study **aims** to analyze the nosological forms of wounds in dogs and cats of various origins for which hydrogel applications are the optimal treatment option, and to confirm their clinical efficacy through experimentation.

**Materials and methods.** The study involved dogs and cats with wounds accompanied by significant tissue defects that prevented primary approximation of the edges. This resulted in the wounds healing by secondary intention, through granulation with the formation of a normotrophic scar. The animals were selected based on absolute clinical and anamnestic indications for surgical wound debridement, followed by conservative treatment and secondary healing.

In this study, the term 'secondary tension' refers to the process of wound healing involving suppuration, the formation of granulation tissue, and subsequent scar remodelling. This type of regeneration is characteristic of wounds with a large tissue deficit, where primary approximation of the edges is impossible, and of wounds complicated by an infectious process.

A total of 34 animals (dogs, n = 19; cats, n = 15) were involved in the study. The empirical base was the private veterinary clinic 'Dovira' (Kharkiv). Each animal underwent a clinical examination using a well-known algorithm, which concluded that there were no pathologies directly affecting the wound healing process. The total observation period lasted 60 days. Skin regeneration was monitored every 15 days. The assessment criteria for tissue regeneration were a reduction in classic signs of inflammation and total epithelialization.

The study included animals of all ages, sexes, and breeds. The clinical cases presented demonstrate the effectiveness of diagnostic and therapeutic measures, as well as the dynamics of the wound-healing process, when treating wounds of various profiles using hydrogel-based products (Fig. 1).



**Figure 1.** Hydrogel-based dressings from different manufacturers: a — Sorbalgon; b — DuoDerm; c — Kaltostat; d — Hydrocoll.

All manipulations with experimental animals were carried out in accordance with the ‘European Convention for the Protection of Vertebrate Animals Used for Experimental and Other Scientific Purposes’ (CE, 1986) and Council Directive 2010/63/EU (CEC, 2010), and under Art. 26 of the Law of Ukraine No. 3447-IV of 21.02.2006 ‘About protection of animals from cruel treatment’ (VRU, 2006) and basic bioethical principles (Simmonds, 2017). Under the current procedure, the research program was reviewed and approved by the Bioethics Committee of the State Biotechnology University.

**Results and discussion. Etiological characteristics of wounds.** Analysis of the etiology of wound injuries showed that in most cases, dogs and cats were diagnosed with bite wounds. The proportion of such injuries was 39% in dogs and 33.3% in cats (Table 1).

Lacerations ranked second in frequency (26.3% in dogs and 20% in cats). Cut wounds were found in 21% of dogs and 20% of cats. Cases of burn injuries are of interest from the perspective of their statistical distribution. Chemical burns caused by various compounds were recorded at the same proportion across species, namely 15.7% in dogs and 20% in cats.

**Table 1 —** Distribution of wounds according to their etiology (n = 34)

Type of damage	Dogs, n = 19		Cats, n = 15	
	n	%	n	%
Bite wound	7	39	5	33.3
Laceration	5	26.3	3	20
Cut wound	4	21	3	20
Chemical burn	3	15.7	3	20
Thermal burn	0	0	1	6.7

However, only one case of thermal burn was recorded in cats, accounting for 6.7% of all cases.

Bite wounds were characterized by irregular edges and variable depths, increasing the risk of bacterial contamination. Lacerations were caused by tissue rupture, had uneven edges, and were usually less infected than bite wounds. Cut wounds were caused by sharp objects, had smooth edges, and were accompanied by significant bleeding. The probable origins of recorded cases of chemical and thermal burns in dogs and cats can be explained by specific conditions of animal husbandry, behavioral responses, and anthropogenic factors.

**Localization of wound damage.** During the clinical examination, a relationship was established between the type of animal and the topographical localization of wounds, as reflected in the statistical distribution of nosological units (Table 2).

**Table 2 —** Distribution of clinical cases of wounds depending on their location (n = 34)

Topographic location	Dogs, n = 19		Cats, n = 15	
	n	%	n	%
Thoracic limb	6	31.5	6	40
Neck	6	31.5	2	13.3
Pelvic limb	4	21.3	3	20
Torso	3	15.7	4	26.7

In cats, the most commonly affected areas were the thoracic limbs (40%) and torso (26.7%), less commonly the pelvic limbs and neck (13.3% each). In dogs, the largest proportions of injuries were to the thoracic limbs and neck (31.5% each), followed by the pelvic limbs (21.3%) and the torso (15.7%).

**The course of the wound healing** process under secondary tension. Based on our clinical observations, the wound-healing process under secondary tension progressed through four consecutive stages: hemostasis, inflammation, proliferation, and remodeling (Table 3).

**Table 3 —** Duration of wound regeneration stages (n = 34)

Regeneration stage (unit)	Duration of the stage (M ± m)
Hemostasis (min)	7.5 ± 0.14
Inflammation (h)	4 ± 0.06
Proliferation (days)	12.5 ± 0.43
Remodeling (days)	57.5 ± 0.14

The hemostasis stage lasted an average of five to ten minutes, which is why most animals arrived at the clinic without signs of active bleeding. The inflammatory stage developed within three to five hours after the injury. Signs of proliferation were observed between days 5 and 20, whereas the remodeling stage lasted between days 55 and 60 after the injury.

The following are several clinical cases involving the use of hydrogel to treat animals with wounds of various origins admitted to a veterinary medical facility.

A cat nicknamed 'Chance' was diagnosed with a chronically infected wound on its neck, showing signs of necrosis and purulent inflammation. This was caused by a bite from another animal. Following surgical debridement of the wound, primary closure was not possible due to significant tissue loss, so secondary tension treatment was chosen, involving the application of hydrogels.

The cat's chronic infected wound gradually healed in stages, corresponding to the classic course of wound healing by secondary tension.

Following surgical debridement (Fig. 2a), necrotic tissue and purulent exudate were removed from the wound. On the 1<sup>st</sup> day of observation (Fig. 2b), a reduction in edema, a clean wound bed, and moderate exudation were noted. Using hydrogel applications helped to maintain a moist environment, which is optimal for further reparative processes.

On the 15<sup>th</sup> day of observation (Fig. 3a), there were clear signs of active granulation in the wound: the wound bed was evenly filled with pink-red granulation tissue; the amount of exudate had decreased significantly; and there were no signs of purulent inflammation. The animal's general condition remained satisfactory. By the 30<sup>th</sup> day (Fig. 3b), the wound defect had further reduced in size due to the contraction of the wound edges and intensive growth of granulation tissue. Signs of marginal epithelialization began to appear, indicating that the healing process had transitioned to the proliferation phase.

On the 45<sup>th</sup> day of observation (Fig. 4a), the wound was significantly smaller in size, and most of it was covered with young epithelium. The granulation tissue became denser and paler, which corresponded to the stage of scar tissue maturation. There were no inflammatory changes. On the 60<sup>th</sup> day (Fig. 4b), almost complete healing of the wound was noted. The surface was covered with formed epithelium, with only a slight scar remaining without signs of inflammation or infection. The functional and cosmetic results of the treatment were assessed as satisfactory.

The prolonged proliferative stage was clearly associated with the animal's immunodeficiency. Complete wound healing occurred, resulting in the formation of a normotrophic scar.

A cat nicknamed 'Asya' developed a chronic wound as a result of a thermal burn to its right hind limb. Following primary surgical treatment, hydrogel applications were used.

The cat's chronic thermal wound gradually healed by secondary tension, which was prolonged due to the depth of the injury and insufficient home care.

Before surgical debridement (Fig. 5a), the wound on the right pelvic limb was characterized by the presence of necrotic tissue, inflammatory changes, and uneven edges typical of thermal burns. On the 1<sup>st</sup> day after primary surgical treatment (Fig. 5b), cleansing of the wound bed from non-viable tissues, a decrease in the severity of inflammation, and moderate exudation were noted. The use of hydrogel applications helped maintain the moist environment necessary for the activation of reparative processes.

On the 15<sup>th</sup> day of observation (Fig. 6a), the first signs of granulation tissue formation appeared in the wound, but the process was uneven. In some areas, there was still high moisture content, and the wound was not cleansing properly, partly due to poor hygiene and the fur around the wound not being removed promptly.

By the 30<sup>th</sup> day of treatment (Fig. 6b), there was a gradual decrease in wound size and more pronounced granulation tissue formation. The wound edges began to contract, but healing remained slow, and maceration of the edges was periodically observed due to violations of the care regimen.

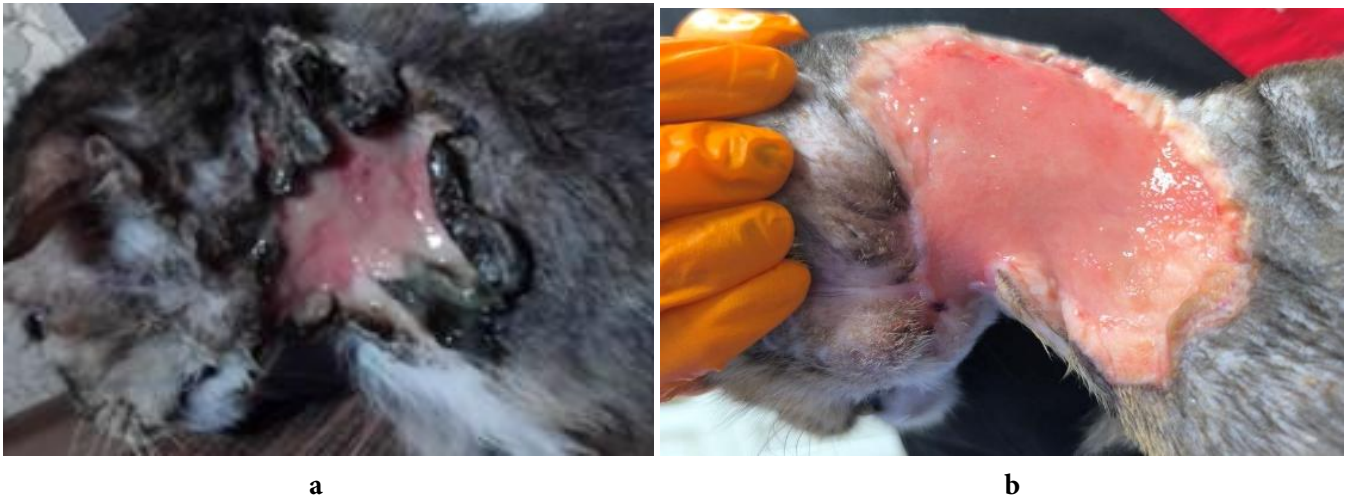The healing process was slowed down due to insufficient wound care at home, in particular, the untimely removal of hair around the injury. On the 45<sup>th</sup> day of observation (Fig. 7a), the wound defect was significantly smaller, and the wound bed was mainly filled with mature granulation tissue. There were clear signs of marginal epithelialization, and inflammation was minimal. The general condition of the animal was assessed as satisfactory.

On the 60<sup>th</sup> day of treatment (Fig. 7b), complete wound healing was noted. The surface of the injury was covered with formed epithelium, and a moderately pronounced scar remained without signs of active inflammation or infection.

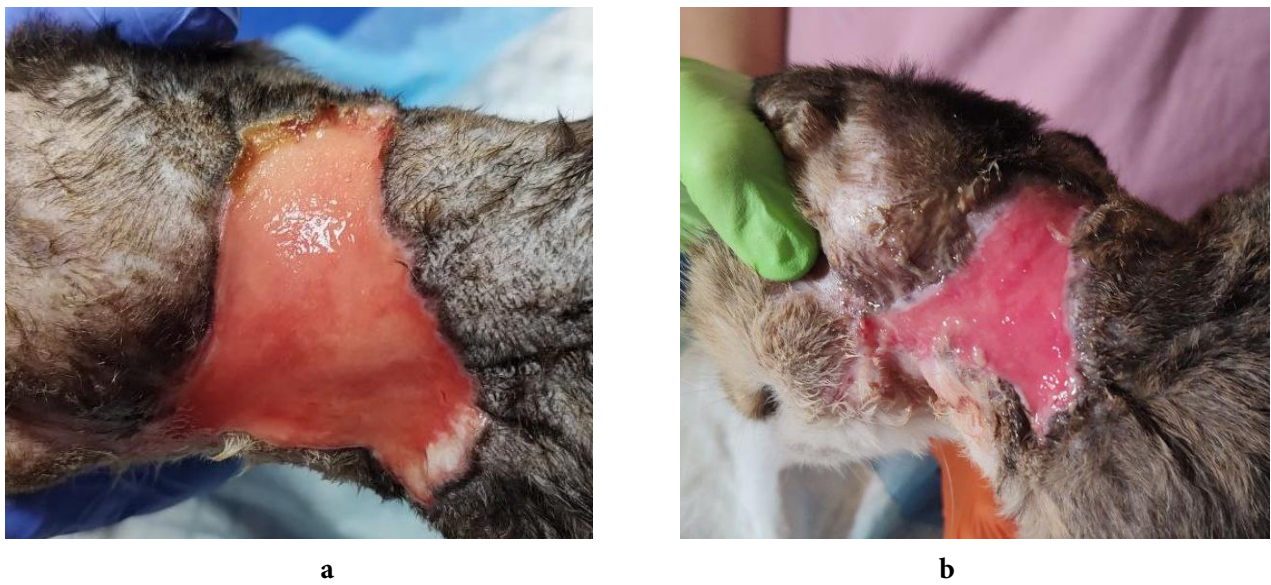
Thus, despite the slow course of reparative processes caused by insufficient wound care at home, the use of hydrogel applications in combination with surgical debridement ensured gradual wound cleansing, granulation tissue formation, epithelialization, and final healing on the 60<sup>th</sup> day of treatment.

A dog named 'Filimon' developed chemical necrosis of the tissues of the left chest limb as a result of doxorubicin extravasation during chemotherapy for lymphoma. Due to intense exudation at the initial stage, hydrocolloid dressings were used, and after the exudation decreased, hydrogel and alginate applications were used. Comprehensive therapy contributed to the gradual cleansing of the wound, reduction of the severity of inflammation patterns, and tissue regeneration.

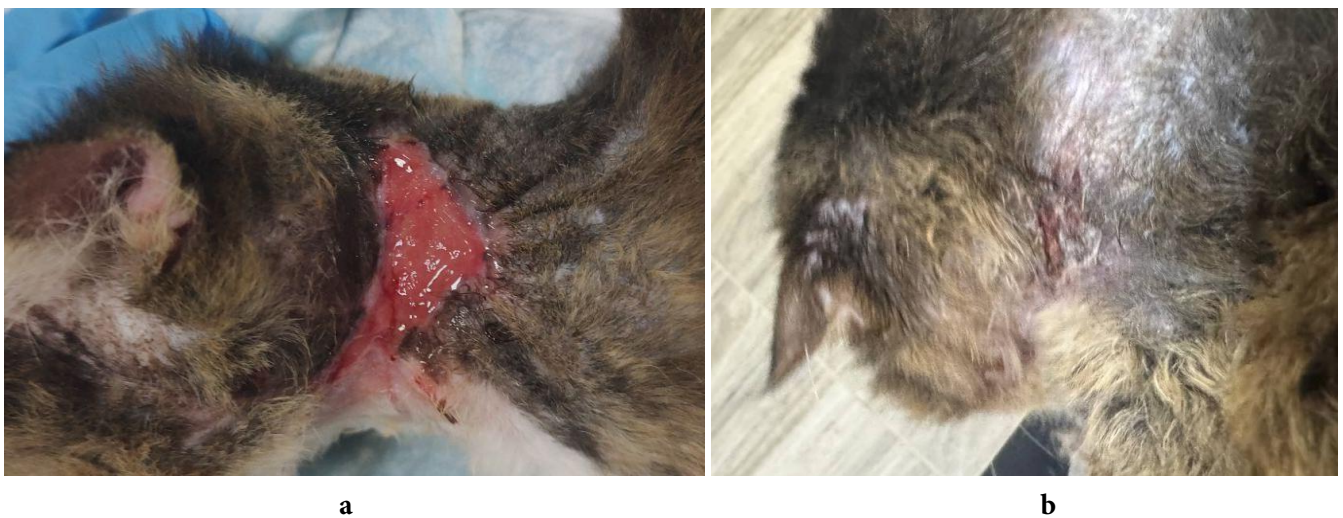Before surgical debridement (Fig. 8a), the wound was characterized by pronounced tissue necrosis, intense exudation, and significant inflammatory changes typical of chemical damage caused by cytostatic drugs. On the 1<sup>st</sup> day after surgical treatment (Fig. 8b), partial cleansing



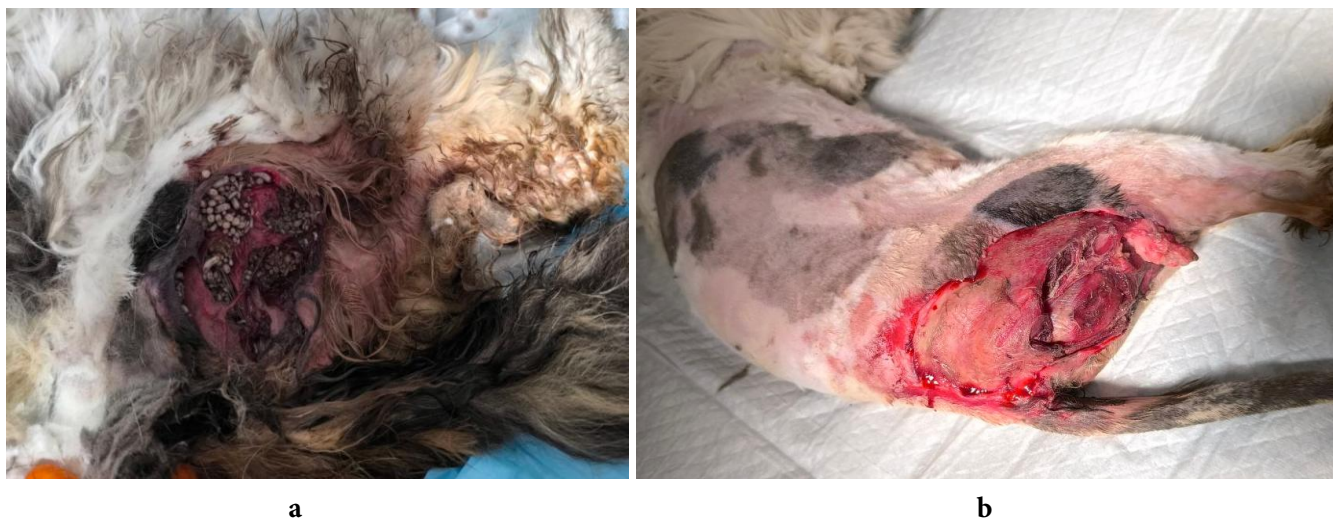**Figure 2.** Chronic infected wound on a cat's neck: a — before surgical treatment; b — 1<sup>st</sup> day after treatment.



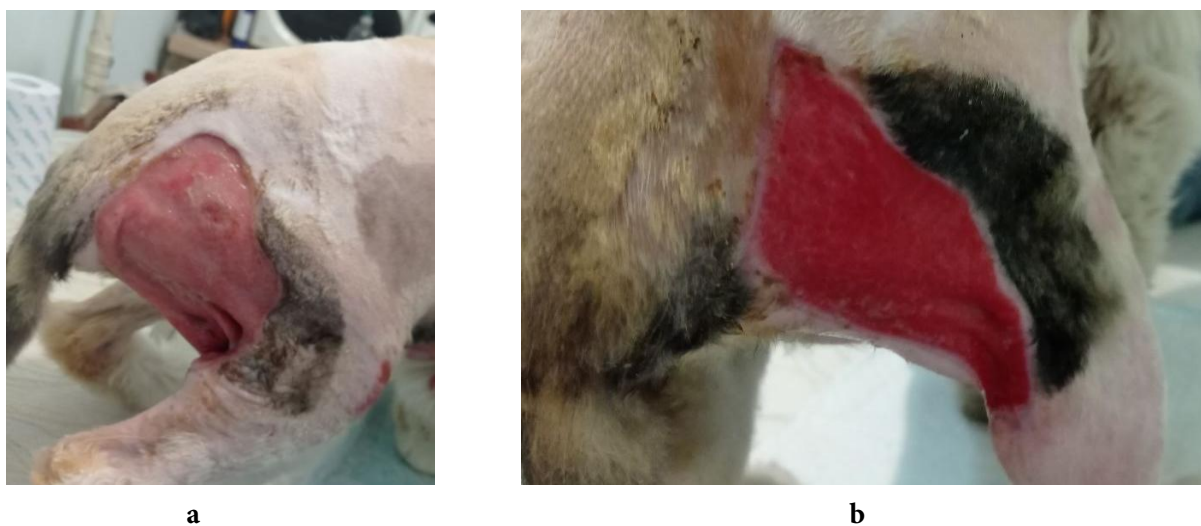
**Figure 3.** Chronic infected wound on a cat's neck: a — on the 15<sup>th</sup> day of observation; b — on the 30<sup>th</sup> day of observation.



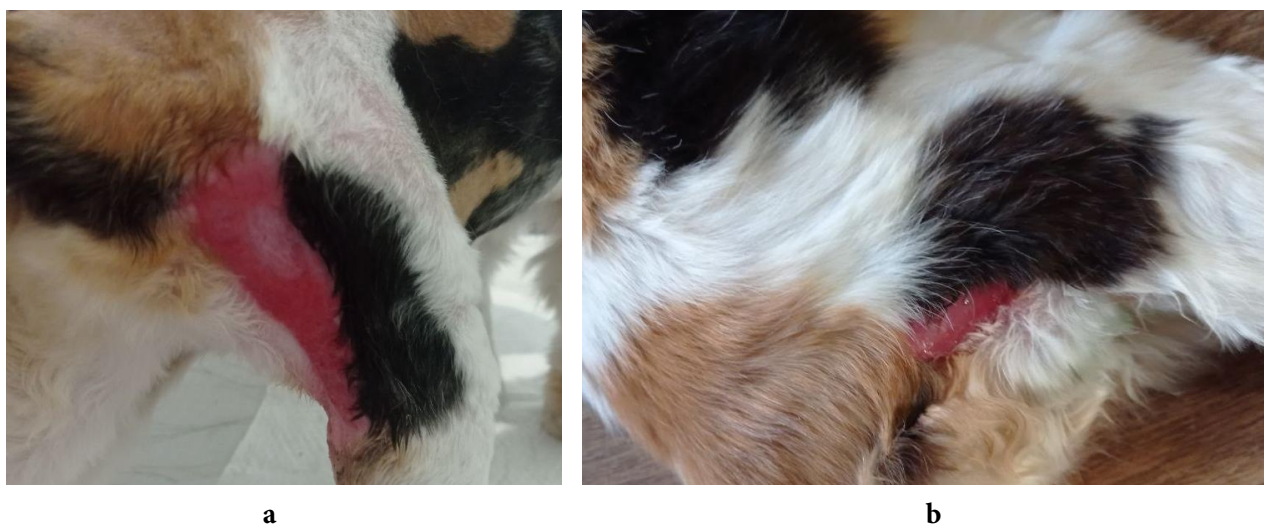
**Figure 4.** Chronic infected wound on a cat's neck: a — on the 45<sup>th</sup> day of observation; b — on the 60<sup>th</sup> day of observation.



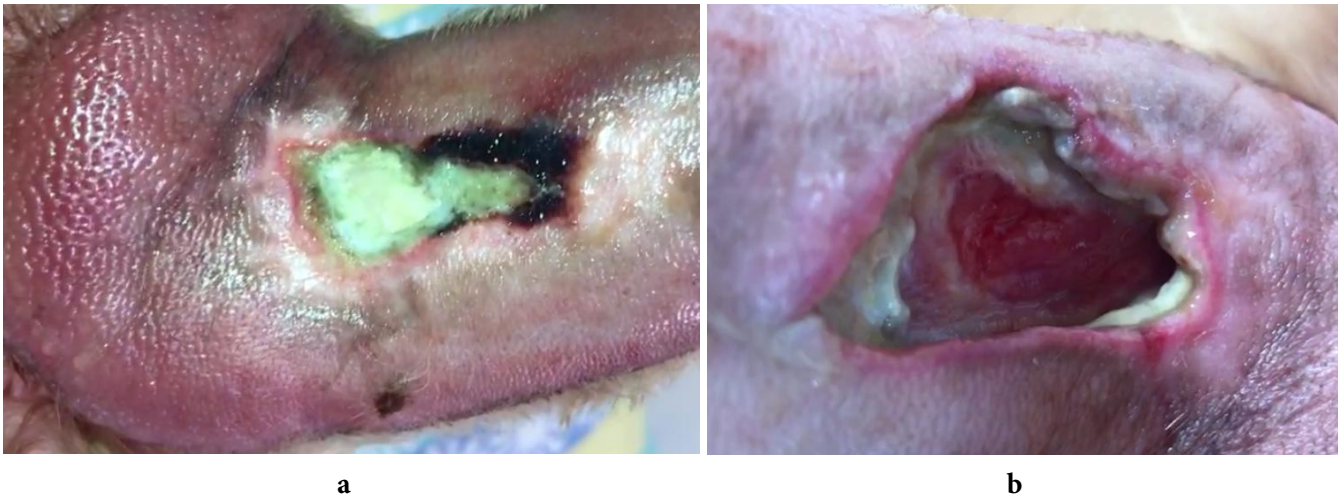
**Figure 5.** Thermal wound on the right pelvic limb of a cat: a — before surgical treatment; b — on the 1<sup>st</sup> day after treatment.



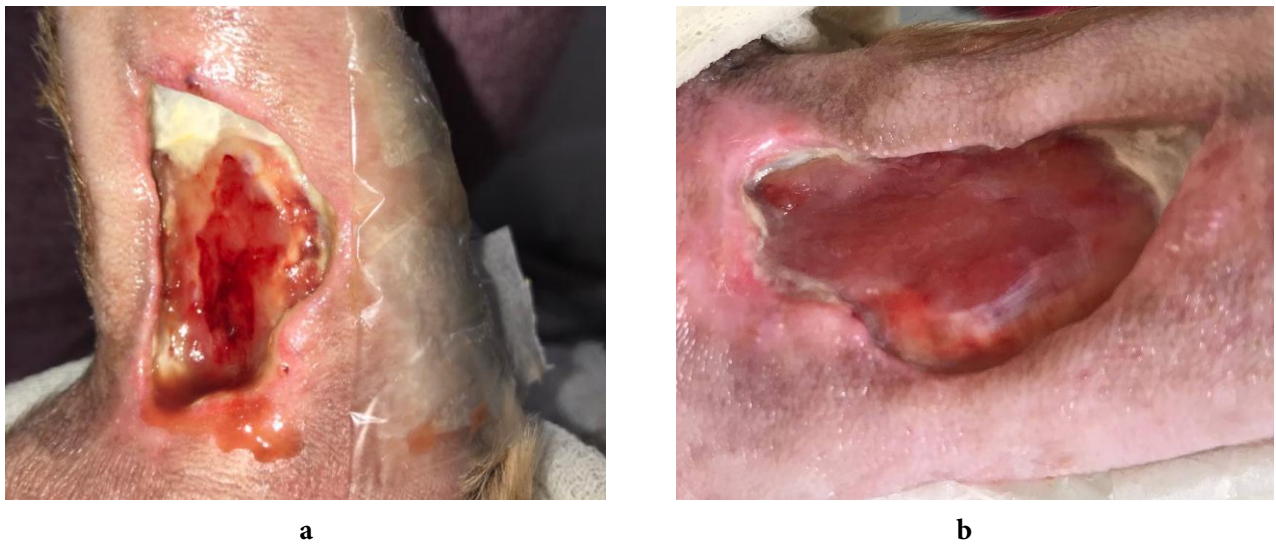**Figure 6.** Thermal wound on the right pelvic limb of a cat: a — on the 15<sup>th</sup> day of observation; b — on the 30<sup>th</sup> day of observation.



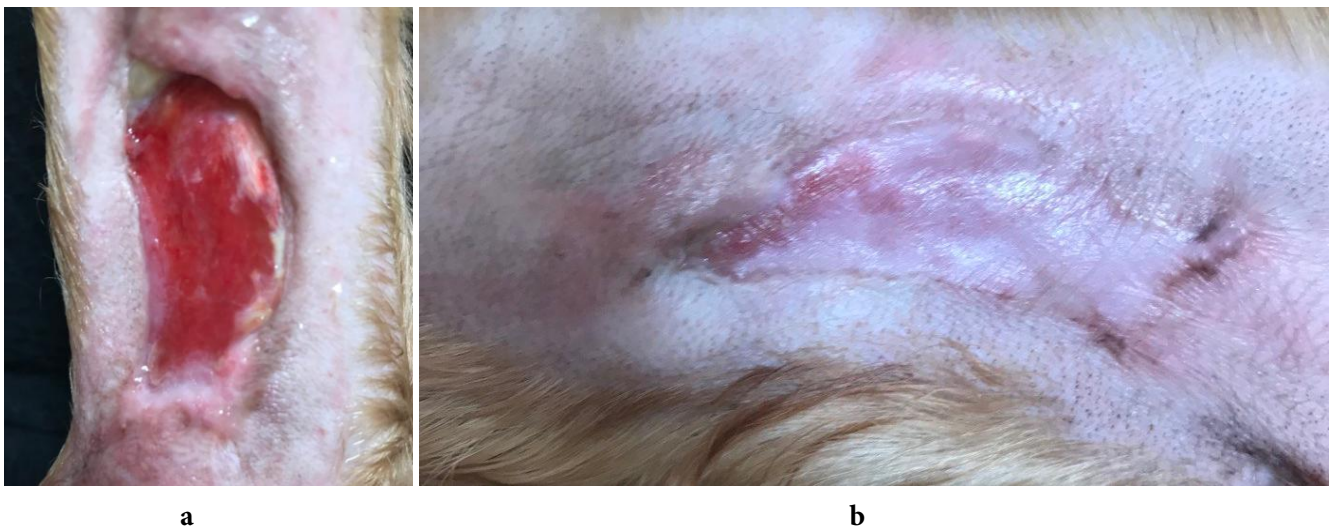
**Figure 7.** Thermal wound on the right pelvic limb of a cat: a — on the 45<sup>th</sup> day of observation; b — on the 60<sup>th</sup> day of observation.



**Figure 8.** Wound on the left thoracic limb of a dog caused by a chemical burn: a — before surgical treatment; b — on the 1<sup>st</sup> day after treatment.



**Figure 9.** Wound on the left thoracic limb of a dog caused by a chemical burn: a — on the 15<sup>th</sup> day of observation; b — on the 30<sup>th</sup> day of observation.



**Figure 10.** Thermal wound on the right pelvic limb of a dog: a — on the 45<sup>th</sup> day of observation; b — on the 60<sup>th</sup> day of observation.

of the wound bed and a reduction in the amount of necrotic tissue were noted, but profuse exudation persisted. In this regard, hydrocolloid dressings were used at the initial stage of treatment, which effectively absorbed the exudate and created a protective environment for the wound.

On the 15<sup>th</sup> day of observation (Fig. 9a), the intensity of exudation decreased significantly, the wound bed became cleaner, and areas of young granulation tissue appeared. The severity of inflammatory patterns decreased, which allowed us to proceed to the use of hydrogel and alginate applications to stimulate reparative processes. On the 30<sup>th</sup> day of treatment (Fig. 9b), active formation of granulation tissue and a gradual reduction in the area of the wound defect were observed. The wound edges became smoother, and there were no signs of secondary infection, indicating stabilization of the local process.

On the 45<sup>th</sup> day of observation (Fig. 10a), most of the wound was filled with mature granulation tissue, and intense marginal epithelialization was occurring. Inflammatory manifestations were minimal, and exudation was practically absent. The general condition of the animal was assessed as satisfactory. On the 60<sup>th</sup> day of treatment (Fig. 10b), almost complete wound healing with scar tissue formation was noted. The surface of the lesion was covered with epithelium, limb function was preserved, and no patterns of active inflammation or necrosis were observed.

The results obtained indicate that the use of hydrogel applications during the clinical management of wound healing under secondary tension promotes wound surface cleansing, maintenance of a moist environment, stimulation of granulation, and scar tissue formation even in complex clinical cases complicated by secondary infection, immunodeficiency, or chemotherapy.

Our observations have shown that tissue healing does not differ depending on the location or type of wound, or the species of animal. However, it does differ significantly depending on the extent of tissue loss due to bodily injury and aggravating factors in the animal's medical history (Knoedler et al., 2023).

Thus, wound healing is a complex, multistage biological process that restores damaged tissue integrity. This occurs through a sequence of interrelated stages, each with its own cellular and molecular mechanisms. Hemostasis is the initial and critically important stage of the wound healing process, ensuring that bleeding stops and that blood remains fluid in the vascular bed. Hemostasis is considered to be the body's initial response to tissue damage and involves three interrelated processes: vasoconstriction (the reflex narrowing of the lumen of the damaged vessel), platelet aggregation resulting in the formation of a primary thrombus, and the activation of the blood coagulation cascade resulting in the formation of a stable fibrin plug. This has been confirmed by data from other researchers (Martin and Nunan, 2015).

Damage to blood and lymph vessels causes blood and lymph to leak out, filling the wound defect and helping to mechanically clean the wound surface of foreign particles and necrotic elements. Almost immediately after the injury, the blood vessels undergo reflex vasoconstriction, and damage to the endothelium leads to the activation of platelets with the subsequent formation of a thrombus directly in the defect area. The formed blood clot performs a protective function, isolating the wound from the external environment, dries out over time with the formation of a scab, and creates optimal conditions for the subsequent stages of tissue repair. The duration of vasoconstriction is usually 5–10 minutes, but the data available in the literature on this indicator are contradictory (Zhao et al., 2016).

The proliferation stage is characterized by active cell growth and migration, particularly of fibroblasts, endothelial cells, and epithelial cells. Fibroblasts gradually fill the wound defect and initiate the synthesis and deposition of the extracellular matrix, which is mainly composed of collagen fibers and glycosaminoglycans. At the same time, neovascularisation occurs to ensure the formation of granulation tissue, which is rich in newly formed capillaries, cellular elements, and the intercellular substances necessary for further regeneration (Kamranvar, Rani and Johansson, 2022).

Remodelling, or tissue reorganization, occurs after the main proliferative processes have been completed. During this period, epithelial cells proliferate in the basal and suprabasal (spiny) layers of the epidermis along the viable edges of the skin defect using pseudopods for migration. The epithelial cells gradually destroy the blood clot and stroma formed in the wound by secreting proteolytic enzymes, particularly collagenases and plasminogen activators. This replaces the temporary covering with fully viable tissue, as confirmed by several scientific studies (Schuster et al., 2022).

Thus, during remodeling, epithelial cells undergo significant phenotypic changes: they lose dense intercellular contacts with the dermis and apical-basal polarity, which ensures their mobility and ability to effectively repair damaged surfaces. Subsequently, collagen fibers are restructured, the number of cellular elements decreases, and the functional integrity of the tissue is gradually restored.

**Conclusions.** 1. The nosological structure of wounds in cats and dogs was determined based on the analysis of the patient journal. Bite wounds were most frequently diagnosed (39% of cases in dogs and 33.3% in cats), with a predominant topographical localization in cats in the thoracic limbs and torso (40% and 26.7% of cases, respectively), and in the thoracic limbs and neck and pelvic limbs, respectively, 31.5% and 21.3% of all registered cases.

2. The characteristics of the wound healing process have been identified. Clinical observations have confirmed the existence of characteristic stages of tissue regeneration: hemostasis, inflammation, proliferation,

and remodeling. Hemostasis stops bleeding, inflammation cleans the wound surface, proliferation forms new granulation tissue, and remodeling completes the healing process by restoring damaged epithelium.

3. It has been established that healing processes do not depend on breed, sex, location, or type of wound. However, important factors affecting healing are the extent of the damage and the presence of a complicating medical history.

4. The clinical effectiveness of hydrogel applications in the comprehensive treatment of purulent wounds has

been confirmed. The findings highlight the necessity of an all-encompassing treatment approach that considers the animal's overall health. This can ensure more effective healing and reduce the risk of complications.

5. It has been experimentally proven that clinical management of non-surgical wounds is based on ensuring secondary tension by creating conditions for hemostasis, healing, and autolysis of necrosis. The main therapeutic measures include surgical wound debridement and the use of interactive hydrocolloid-based dressings.

## References

- Beraja, G. E., Gruzmark, F., Pastar, I. and Lev-Tov, H. (2025) 'What's new in wound healing: treatment advances and microbial insights', *American Journal of Clinical Dermatology*, 26(5), pp. 677–694. doi: [10.1007/s40257-025-00953-9](https://doi.org/10.1007/s40257-025-00953-9).
- CE (The Council of Europe). (1986) *European Convention for the Protection of Vertebrate Animals Used for Experimental and Other Scientific Purposes*. (European Treaty Series, No. 123). Strasbourg: The Council of Europe. Available at: <https://conventions.coe.int/treaty/en/treaties/html/123.htm>.
- CEC (The Council of the European Communities) (2010) 'Directive 2010/63/EU of the European Parliament and of the Council of 22 September 2010 on the protection of animals used for scientific purposes', *The Official Journal of the European Communities*, L 276, pp. 33–79. Available at: <http://data.europa.eu/eli/dir/2010/63/oj>.
- Cochetti, G., Abraha, I., Randolph, J., Montedori, A., Boni, A., Arezzo, A., Mazza, E., Rossi De Vermandois, J. A., Cirocchi, R. and Mearini, E. (2020) 'Surgical wound closure by staples or sutures?', *Medicine*, 99(25), p. e20573. doi: [10.1097/md.00000000000020573](https://doi.org/10.1097/md.00000000000020573).
- De Szalay, S. and Wertz, P. (2023) 'Protective barriers provided by the epidermis', *International Journal of Molecular Sciences*, 24(4), p. 3145. doi: [10.3390/ijms24043145](https://doi.org/10.3390/ijms24043145).
- Fani, N., Moradi, M., Zavari, R., Parvizpour, F., Soltani, A., Arabpour, Z., and Jafarian, A. (2024) 'Current advances in wound healing and regenerative medicine', *Current Stem Cell Research & Therapy*, 19(3), pp. 277–291. doi: [10.2174/1574888X18666230301140659](https://doi.org/10.2174/1574888X18666230301140659).
- Fernández-Guarino, M., Bacci, S., Pérez González, L. A., Bermejo-Martínez, M., Cecilia-Matilla, A. and Hernández-Bule, M. L. (2023) 'The role of physical therapies in wound healing and assisted scarring', *International Journal of Molecular Sciences*, 24(8), p. 7487. doi: [10.3390/ijms24087487](https://doi.org/10.3390/ijms24087487).
- Gillespie, B. M., Walker, R. M., McInnes, E., Moore, Z., Eskes, A. M., O'Connor, T., Harbeck, E., White, C., Scott, I. A., Vermeulen, H. and Chaboyer, W. (2020) 'Preoperative and postoperative recommendations to surgical wound care interventions: A systematic meta-review of Cochrane reviews', *International Journal of Nursing Studies*, 102, p. 103486. doi: [10.1016/j.ijnurstu.2019.103486](https://doi.org/10.1016/j.ijnurstu.2019.103486).
- Holmes, S. P., Rivera, S., Hooper, P. B., Slaven, J. E. and Que, S. K. T. (2022) 'Hydrocolloid dressing versus conventional wound care after dermatologic surgery', *JAAD International*, 6, pp. 37–42. doi: [10.1016/j.jdin.2021.11.002](https://doi.org/10.1016/j.jdin.2021.11.002).
- Huang, C., Dong, L., Zhao, B., Lu, Y., Huang, S., Yuan, Z., Luo, G., Xu, Y. and Qian, W. (2022). 'Anti-inflammatory hydrogel dressings and skin wound healing', *Clinical and Translational Medicine*, 12(11), p. e1094. doi: [10.1002/ctm2.1094](https://doi.org/10.1002/ctm2.1094).
- Jeschke, M. G., van Baar, M. E., Choudhry, M. A., Chung, K. K., Gibran, N. S. and Logsetty, S. (2020) 'Burn injury', *Nature Reviews Disease Primers*, 6(1), p. 11. doi: [10.1038/s41572-020-0145-5](https://doi.org/10.1038/s41572-020-0145-5).
- Kamranvar, S. A., Rani, B. and Johansson, S. (2022) 'Cell cycle regulation by integrin-mediated adhesion', *Cells*, 11(16), p. 2521. doi: [10.3390/cells11162521](https://doi.org/10.3390/cells11162521).
- Knoedler, S., Broichhausen, S., Guo, R., Dai, R., Knoedler, L., Kauke-Navarro, M., Diatta, F., Pomahac, B., Machens, H. G., Jiang, D. and Rinkevich, Y. (2023) 'Fibroblasts — the cellular choreographers of wound healing', *Frontiers in Immunology*, 14, p. 1233800. doi: [10.3389/fimmu.2023.1233800](https://doi.org/10.3389/fimmu.2023.1233800).
- Liu, J., Jiang, W., Xu, Q., and Zheng, Y. (2022) 'Progress in antibacterial hydrogel dressing', *Gels*, 8(8), p. 503. doi: [10.3390/gels8080503](https://doi.org/10.3390/gels8080503).
- Martin, P. and Nunan, R. (2015) 'Cellular and molecular mechanisms of repair in acute and chronic wound healing', *British Journal of Dermatology*, 173(2), pp. 370–378. doi: [10.1111/bjd.13954](https://doi.org/10.1111/bjd.13954).
- Ousey, K., Cutting, K. F., Rogers, A. A. and Rippon, M. G. (2016) 'The importance of hydration in wound healing: Reinvigorating the clinical perspective', *Journal of Wound Care*, 25(3), pp. 122–130. doi: [10.12968/jowc.2016.25.3.122](https://doi.org/10.12968/jowc.2016.25.3.122).
- Saravi, B., Goebel, U., Hassenzahl, L. O., Jung, C., David, S., Feldheiser, A., Stopfkuchen-Evans, M. and Wollborn, J. (2023) 'Capillary leak and endothelial permeability in critically ill patients: A current overview', *Intensive Care Medicine* Experimental, 11(1), p. 96. doi: [10.1186/s40635-023-00582-8](https://doi.org/10.1186/s40635-023-00582-8).
- Schuster, R., Younesi, F., Ezzo, M. and Hinz, B. (2022) 'The role of myofibroblasts in physiological and pathological tissue repair', *Cold Spring Harbor Perspectives in Biology*, 15(1), p. a041231. doi: [10.1101/cshperspect.a041231](https://doi.org/10.1101/cshperspect.a041231).
- Simmonds, R. C. (2017) 'Chapter 4. Bioethics and animal use in programs of research, teaching, and testing', in Weichbrod, R. H., Thompson, G. A. and Norton, J. N. (eds.) *Management of Animal Care and Use Programs in Research, Education, and Testing*. 2<sup>nd</sup> ed. Boca Raton: CRC Press, pp. 35–62. doi: [10.1201/9781315152189-4](https://doi.org/10.1201/9781315152189-4).
- VRU (Verkhovna Rada Ukraine) (2006) 'Law of Ukraine No. 3447-IV of 21.02.2006 'About protection of animals from cruel treatment' [Zakon Ukrainy № 3447-IV vid 21.02.2006 'Pro zakhyst tvaryn vid zhorstokoho povodzhennia'], *News of the Verkhovna Rada of Ukraine [Vidomosti Verkhovnoi Rady Ukrainy]*, 27, art. 230. Available at: <https://zakon.rada.gov.ua/laws/3447-15>. [in Ukrainian].
- Wilkinson, H. N. and Hardman, M. J. (2020) 'Wound healing: Cellular mechanisms and pathological outcomes', *Open Biology*, 10(9), p. 200223. doi: [10.1098/rsob.200223](https://doi.org/10.1098/rsob.200223).

Yu, H. P., Chaudry, I. H., Choudhry, M. A., Hsing, C. H., Liu, F. C. and Xia, Z. (2015) 'Inflammatory response to traumatic injury: clinical and animal researches in inflammation', *Mediators of Inflammation*, 2015, p. 729637. doi: [10.1155/2015/729637](https://doi.org/10.1155/2015/729637).

Zaika, P. O., Kochevenko, A. S., Slyusarenko, D. V. and Severin, B. S. (2024) 'Use of hydrocolloid dressing in the treatment of wounds in areas with skin deficiency' [Vykorystannia hidrokolojoidnoi poviazky v likuvanni ran na diliankakh iz defitsytom shkiry], *Veterinary Science*,

*Technologies of Animal Husbandry and Nature Management [Veterynariia, tekhnolohii tvarynnystva ta pryrodokorystuvannia]*, 10, pp. 38–45. doi: [10.31890/vttp.2024.10.04](https://doi.org/10.31890/vttp.2024.10.04). [in Ukrainian].



Zhang, H., Cheng, J. and Ao, Q. (2021) 'Preparation of alginate-based biomaterials and their applications in biomedicine', *Marine Drugs*, 19(5), p. 264. doi: [10.3390/md19050264](https://doi.org/10.3390/md19050264).

Zhao, R., Liang, H., Clarke, E., Jackson, C. and Xue, M. (2016) 'Inflammation in chronic wounds', *International Journal of Molecular Sciences*, 17(12), p. 2085. doi: [10.3390/ijms17122085](https://doi.org/10.3390/ijms17122085).

Received 28.11.2025

Accepted 27.01.2026

Published 12.02.2026

2026 © Kazantsev R. H.  [0000-0002-4479-1516](https://orcid.org/0000-0002-4479-1516), Kryvoruchenko D. O.  [0000-0002-2044-8019](https://orcid.org/0000-0002-2044-8019),

Slyusarenko D. V.  [0000-0001-8214-0637](https://orcid.org/0000-0001-8214-0637), Zaika P. O.  [0000-0003-0321-4795](https://orcid.org/0000-0003-0321-4795),

Syniahovska K. A.  [0000-0003-4482-4813](https://orcid.org/0000-0003-4482-4813)



This is an open access article under the terms of the [Creative Commons Attribution-NonCommercial-NoDerivs License](https://creativecommons.org/licenses/by-nc-nd/4.0/), which permits use and distribution in any medium, provided the original work is properly cited, the use is non-commercial and no modifications or adaptations are made