

CURRENT EPIZOOTOLOGICAL MANIFESTATIONS OF CANINE PARVOVIRUS INFECTION BASED ON CLINICAL AND PATHOLOGICAL CRITERIA AND SEASONALITY

Zamoshnikov V. O., Borovkov S. B., Yakymchuk I. M., Sytiuk M. P.

Institute of Veterinary Medicine of the National Academy of Agrarian Sciences of Ukraine, Kyiv, Ukraine, e-mail: vlazmk@gmail.com

Summary. Canine parvovirus infection is a highly contagious viral disease caused by the canine parvovirus (CPV-2), characterized by acute hemorrhagic enteritis, leukopenia, and myocarditis. This study aimed to assess the current epizootiological manifestations of canine parvovirus infection based on clinical and pathological criteria and seasonality at the 'Zoolux' network of veterinary clinics in Kyiv. To this end, 3,760 rapid tests were conducted to detect parvovirus in dogs of various breeds at the 'Zoolux' veterinary clinic network in Kyiv between 2013 and 2025. Detection of the canine parvovirus antigen in dog feces was performed using immunochromatographic analysis with special reagent kits (the 'VeChek CPV Ag' and 'VetExpert CPV Ag' kits). Of the 3,760 rapid tests conducted, 679 (18.1%) returned positive results. Despite a pronounced summer-fall seasonality, which significantly exceeded the incidence in winter ($p < 0.05$) with peaks in October and June (12.5% and 10.8% of cases, respectively), parvovirus infection in dogs is observed throughout the year. The main clinical manifestations of viral enteritis in the dogs we examined were lethargy, vomiting, watery bloody feces with a sharp foul odor, refusal of food and water; signs of cardiovascular and respiratory system involvement were observed less frequently. Further research is needed to identify methods for the early and rapid diagnosis of the etiology of viral enteritis in dogs, which will allow for the precise identification of the causative agent and, consequently, the selection of effective treatment methods for the animal and the prevention of the spread of infection through the use of specific preventive measures

Keywords: dogs, viral enteritis, enteritis

Introduction. Despite significant advances in veterinary medicine, infectious diseases in animals, including dogs, remain a pressing issue. Most infectious and parasitic agents damage the gastrointestinal tract of dogs, causing symptoms ranging from mild diarrhea to severe enteritis, which can lead to dehydration, organ damage, and ultimately, death. One of the most common agents is the canine parvovirus (CPV-2), which causes parvovirus infection.

Canine parvovirus infection is a highly contagious viral disease caused by CPV-2 (canine parvovirus enteritis). It is characterized by acute gastroenteritis and is often accompanied by dehydration, myocarditis, and leukopenia. While the disease can occur at any age, puppies under six months old are most susceptible. It is believed that animals are more susceptible to parvovirus at this age due to the immaturity of their immune systems and the decline of maternal immune protection (Hasan et al., 2017; Ogbu et al., 2016; Tagorti, 2018).

Parvovirus enteritis in dogs is observed throughout the year, with periods of seasonal increases. However, data on the seasonality of parvovirus in the literature vary significantly, which may be primarily due to the climatic characteristics of a particular region. For example, Ngu Ngwa et al. (2020) noted a peak in parvovirus incidence in dogs in Cameroon in November, January, and December; whereas in Nigeria, according to data from Agada et al. (2022), the highest incidence occurred during the dry season in that region, specifically December–March, with a peak in January; in China, according to data from Dong et al. (2020), it occurred in the spring; and in India, according to data from

Naveenkumar et al. (2025), it occurred during the winter and in July. At the same time, Naveenkumar et al. (2025) established a positive correlation between the increase in cases of canine parvovirus and maximum temperature (with a lag of 11 months), relative humidity in the morning (with a lag of 1 month), and precipitation (with a lag of 10 months); and negative correlations with maximum temperature (with a lag of 1 and 6 months), minimum temperature (with a lag of 4 months), relative humidity in the morning (with a lag of 7 months), relative humidity in the evening (with a lag of 7 months), precipitation (with a lag of 2 and 7 months), and wind speed (with a lag of 4 months) (Naveenkumar et al., 2025).

Canine parvovirus (CPV-2) is a member of the Parvoviridae family, which consists of the smallest spherical viruses; it contains DNA and lacks a lipoprotein envelope. This family includes more than 30 species belonging to three genera: *Parvovirus*, *Dependovirus*, and *Densovirus*. The genus *Parvovirus* consists of autonomous (complete, non-defective) viruses and can cause inflammation of the intestine (enteritis), myocardium (myocarditis), brain tissue (encephalitis, hemorrhagic encephalopathy), liver (hepatitis), embryonic and fetal tissues (leading to their death), suppression of hematopoiesis and lymphopoiesis (causing panleukopenia with a reduced immune response), and possible growth retardation in affected animals (Lisova et al., 2022; Radzykhovskiy, 2021).

In experimental studies, the incubation period of the disease was 4–5 days after infection of the animal; however, according to epidemiological data, it lasts

7–14 days. Active viral shedding by an infected animal begins as early as the asymptomatic incubation period (3–4 days after exposure) and lasts for 7–10 days. The production of virus-neutralizing, hemagglutinating, and complement-fixing antibodies begins as early as 5 days after the animal is infected. The viremic phase of the disease is characterized by initial viral replication in the tonsils and lymph nodes of the oropharynx, from where it spreads to other organs via lymphoid tissues such as the thymus, spleen, Peyer's patches, and lymph nodes. Canine parvovirus can be detected in the epithelium of the entire gastrointestinal tract, spleen, bone marrow, thymus, tonsils, lymph nodes, myocardium, kidneys, liver, and fetal tissues in a pregnant animal (Greene and Decaro, 2016). If a pregnant dog becomes ill, generalized intrauterine infection of the fetus or even termination of pregnancy may occur.

Many people assume that the sudden onset of bloody, foul-smelling diarrhea in a young dog is always caused by a CPV infection. However, this is far from the case. First, not all dogs with bloody diarrhea (regardless of whether vomiting is present) are infected with parvovirus. Second, parvovirus can also cause non-hemorrhagic diarrhea. Furthermore, it is rare for all typical clinical signs of parvovirus to be observed simultaneously. Acute hemorrhagic diarrhea syndrome in dogs can result from parvovirus infection or the action of other infectious agents. These pathogens include canine coronavirus, canine distemper virus, and *Clostridium perfringens* type A.

Most animals (about 80% of dogs), primarily older ones, experience a subclinical disease course; 10% have a moderate-to-severe course, and only 10% have a severe course (Sato-Takada et al., 2022).

A characteristic feature of parvovirus is its active replication in rapidly dividing cells, i. e., those with high mitotic activity. This fact explains its tropism specifically for intestinal epithelium and lymphoid tissue cells. The virus's entry into the intestine and its replication there lead to the death of embryonic epithelial cells of the intestinal glands, followed by epithelial desquamation and shortening of the villi, causing vomiting, hemorrhagic diarrhea, dehydration, fever, central nervous system depression, shock, and even death (Lisova et al., 2022). The decrease in intestinal immune reactivity is associated with the development of secondary Gram-negative and anaerobic bacterial infections, which cause additional complications such as bacteremia, endotoxemia, disseminated intravascular coagulation, systemic inflammatory response, and cardiorenal syndrome (Zamoshnikov, 2024a; Greene and Decaro, 2016).

Currently, myocarditis (i. e., inflammation of the myocardium) is a relatively rare clinical syndrome associated with parvovirus infection and occurs primarily in puppies born to unvaccinated females or those that are malnourished (Ford et al., 2017; Lixandru and Ursachi, 2020). In addition, it is more common in young puppies under 1–2 months of age, whereas the

enteritic form predominates in older animals. Myocarditis may often be completely asymptomatic, or it may present with mild diarrhea, cyanosis of the mucous membranes, wheezing, labored breathing, and a rapid, weak pulse (Lisova et al., 2022). The development of myocarditis is characterized by the onset of myocardial necrosis and inflammation, leading to acute heart failure, which may clinically manifest as pulmonary edema and/or hepatic venous congestion. Quite often, the animal dies precisely because of these complications. If the animal survives this acute phase, it most often develops replacement or interstitial fibrosis and develops chronic heart failure.

The pathomorphological changes that are typically characteristic of parvovirus enteritis include hemorrhagic-necrotic inflammation of the small intestinal mucosa and hyperplasia with atrophy of the lymphoid tissue of the intestinal tract. Often, there is also eosinophilic alternative myocarditis. Histological changes in dogs that died from parvovirus correspond to intestinal and/or cardiac forms of the disease. In the intestinal form, the main changes are observed in the intestine and include hemorrhagic enteritis, hepatitis with dystrophic changes in hepatocytes, serous-hemorrhagic inflammation of the mesenteric lymph nodes, splenomegaly, and dystrophic and necrotic changes in the pancreas. In the cardiac form, acute alternative myocarditis is often accompanied by hemorrhages in the lungs and atelectatic foci (Radzykhovskiy, 2021).

According to data from the experimental reproduction of parvovirus infection in dogs, the morphological criteria for the disease include hemorrhagic inflammation of the jejunum, ileum, and mesenteric lymph nodes; necrosis of intestinal lymphoid tissue; and hemorrhages in the mucous and serous membranes of the small intestine. Lesions of the large intestine are segmental and predominantly localize in the cecum and colon (Radzykhovskiy, 2021).

Due to the variability in clinical presentation, the prevalence and contagiousness of the infection, and the economic and psychological impact on pet owners, early diagnosis and personalized etiological and pathophysiological treatment are critical for enterovirus infections in dogs, including parvovirus. A comprehensive diagnosis is necessary, taking into account the dog's medical history (onset and progression of clinical signs, condition before disease onset, contact with potentially infected animals, living conditions, age, acquisition source, administered preventive vaccinations, and prior medication use), physical examination findings, vital signs, and hematological and biochemical analysis results. Although virological testing is the most accurate method for determining the cause of a viral infection, it is not widely used due to the time-consuming nature of the procedure, the need for expensive equipment, technical difficulties, and the high cost. Therefore, rapid diagnostic methods are more commonly used in practice. These methods allow one to

'circumvent' the limitations and complexities of virological testing while offering high sensitivity and specificity for detecting the pathogen's antigens. These methods primarily include the immunochromatographic assay (ICA) and the polymerase chain reaction (PCR) (Ilchenko and Tsarenko, 2020; Prosolenko, 2023).

This study aims to assess the current epizootological manifestations of canine parvovirus infection based on clinical and pathological criteria and seasonality at the 'Zoolux' network of veterinary clinics in Kyiv (Ukraine).

Materials and methods. To achieve the stated objective, an analysis and synthesis of current scientific and methodological literature was conducted, with searches performed in Google Scholar, Scopus, PubMed, Web of Science, and EuroPub databases.

Additionally, an analysis was conducted of the veterinary records of dogs of various breeds that presented with symptoms of enterovirus infection at the 'Zoolux' network of veterinary clinics in Kyiv between 2013 and 2025.

The etiological factor of the infection was determined using rapid methods to detect the pathogen's antigen in the feces or vomit of affected animals via immunochromatographic analysis. The canine parvovirus antigen was detected using the 'VeChek CPV Ag' (Quicking Biotech, China) and 'VetExpert CPV Ag' (VetExpert, Republic of Korea) test kits. Testing and interpretation of the results were performed according to the instructions for these kits (BIOVET.UA, 2026).

The clinical manifestations of parvovirus infection in the examined dogs, the results of additional diagnostic methods, and the seasonality of the disease were analyzed and systematized.

Under the current procedure, the research program was reviewed and approved by the Bioethics Committee of the Institute of Veterinary Medicine of the National Academy of Agrarian Sciences of Ukraine.

The results were processed by methods of variation statistics using Excel 2010 and StatSoft Statistica 10.0. To compare mean values Student's *t*-test was used (Van Emden, 2019).

Results and discussion. A test to detect CPV antigen was performed on 3,760 dogs, 679 of which (18.1%) tested positive. In the remaining cases, a different cause of enteritis was identified, medical care was sought too late, or the test was performed too early when the viral load in the samples was below the diagnostic sensitivity of the test system.

According to the literature, three clinical forms of parvovirus infection are recognized: enteritic (intestinal), myocardial (cardiac), and mixed.

The enteritic (intestinal) form predominantly occurs between 2 and 6 months of age. The disease begins suddenly with loss of appetite, sometimes accompanied by mild fever and abdominal tenderness on palpation; abdominal muscle rigidity may also be present, and vomiting occurs, often containing mucus and bile; Diarrhea usually begins within a day, with stools that are

watery, foul-smelling, yellowish, and mixed with blood or completely saturated with it. Vomiting and diarrhea contribute to dehydration, the development of toxicosis, and often the onset of shock. In about one-third of cases, leukopenia is observed during the first 4–5 days of the disease, often accompanied by a fever. Older dogs may experience a subclinical form of the disease for 2–3 weeks, often manifesting as a sharp loss of appetite and lethargy, but rarely accompanied by other gastrointestinal disorders (Mazzaferro, 2020). After recovering from the disease, dogs may experience some growth retardation; in males, hypospermia or azoospermia (complete absence of sperm) may occur. If a pregnant female dog is infected, pregnancy loss, stillbirth, or fetal developmental abnormalities may occur (persistent cleft palate, nasal and lip abnormalities, brain hypoplasia) (Streletskyi, 2022).

The myocardial (cardiac) form of parvovirus infection in dogs occurs much less frequently than the enteritis form, in puppies without active or passive antibodies under 2 months of age, most often by 4 weeks of age, which is primarily associated with the high mitotic activity of cardiomyocytes during this period of life. More than 50% of puppies die from acute heart failure, which occurs suddenly in previously healthy puppies and is accompanied by a weak, rapid pulse, labored breathing, cyanosis of the mucous membranes, collapse, and convulsions. In puppies older than 8 weeks, subacute heart failure is more common; it can last several months and is characterized by weakness, shortness of breath, prostration, cardiac arrhythmias, and the development of congestive changes in the lungs and liver (Streletskyi, 2022). In addition, some dogs may develop acute kidney injury against a background of acute heart failure, i. e., cardiorenal syndrome (Zamoshnikov, 2024b; Ford et al., 2017; Lixandru and Ursachi, 2020).

The mixed form of the disease is rare and is characterized by combined involvement of the gastrointestinal tract and the heart.

Macroscopic changes observed during autopsies of dogs that have died from the enteritic form of parvovirus infection are characterized by external signs of dehydration, while the abdominal cavity may contain a small amount of straw-colored fluid; the intestines may be empty or contain bile, sometimes hemorrhagic fluid; their mucous membrane is bright red with signs of severe inflammation; intussusception with hyperperistalsis is often observed; the mesenteric lymph nodes are edematous, enlarged, and hemorrhagic; Peyer's patches are often hemorrhagic as well; erosions and vascular inflammation may be observed in the internal organs (Goralskii, Radsikhovskii and Zaika, 2018; Prosolenko, 2023).

Changes characteristic of the myocardial form of the disease include: in acute heart failure, the lungs are edematous, with localized reddish-gray areas, predominantly located in the middle and cranial lobes; the bronchi contain mucous exudate; hemorrhages in the spleen, often with infarcts, and frequently an

enlargement of the spleen; in subacute heart failure, signs of congestion in the liver and fluid accumulation in the serous membranes (hydrothorax, ascites, hydropericardium) are observed (Sato-Takada et al., 2022).

Morphological changes in the small intestine include focal lesions of the epithelial crypts with destruction of the epithelial villi; eosinophilic inclusions are found in the crypt nuclei. In the mesenteric lymph nodes, Peyer's patches, thymus, and spleen, there is destruction of lymphocytes and necrosis of lymphoid tissue. Morphological changes in myocarditis are characterized by interstitial inflammation of the heart muscle, its edema, and the accumulation of lymphocytes, histiocytes, plasma cells, and intranuclear inclusions in varying amounts. It is generally believed that necrosis of lymphoid tissue and its depletion in the lymph nodes, Peyer's patches, thymus, and spleen are the main pathomorphological features of parvovirus infection (Prosolenko, 2023; Mazzaferro, 2020).

In the thymus, the blood vessels dilate, leading to organ swelling and disruption of its cellular structure; lymphocyte differentiation in the cortical and medullary regions of the lobules is impaired. As a result of red blood cell breakdown, hemosiderin accumulates in the red pulp of the spleen, causing it to become edematous. Renal involvement is characterized by hemorrhages in the stroma of both the cortex and medulla, progressive edema of the renal glomeruli with their subsequent breakdown and necrosis, and dystrophic changes in the epithelium of all segments of the tubules. The liver is edematous; venous stasis, granular degeneration of hepatocytes, and their disintegration may be observed. Granular and hydropic degeneration may occur in the pancreas (Radzykhovskiy, 2021).

The clinical manifestations of viral enteritis in the dogs we examined included lethargy, vomiting, watery bloody feces with a sharp foul odor, refusal of food and water, and, less frequently, signs of cardiovascular and respiratory system involvement (Fig. 1).

Examinations and treatments at clinics often had to be performed in a veterinary hospital with intensive care units during infusion therapy to rehydrate the animal, using an infusion stand with an infusion pump (for precise control of the dose and rate of drug administration) or an IV drip (for the intravenous administration of drugs or fluids) (Fig. 2).

In general, Fig. 2 shows a typical layout of an intensive care unit in a veterinary clinic for the treatment of animals with parvovirus enteritis. The core of the unit consists of equipment for infusion therapy (infusion pumps, volumetric infusion pumps, infusion stands), patient support (an oxygen concentrator or oxygen source for animal oxygen therapy), and a stationary enclosed patient box (an isolated area for intensive monitoring, with temperature control and stress minimization).

When conducting additional diagnostic tests, anemia of varying severity was predominantly detected; occasionally, hemoglobin and red blood cell levels were




Figure 1. Predominant clinical signs of parvovirus infection in the dogs examined.

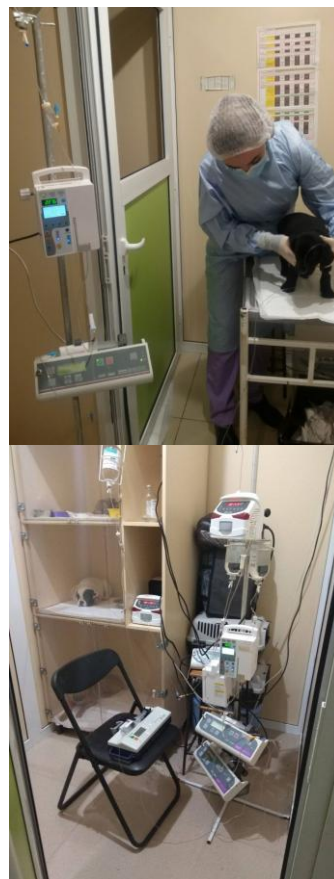

Figure 2. Examination and treatment procedures, and a view of the hospital with an intensive care unit at the 'Zoolux' veterinary clinic network in Kyiv.

within normal limits, which was due to hemoconcentration caused by the animal's dehydration. Less frequently, leukopenia, elevated erythrocyte sedimentation rate (ESR), and decreased total blood protein were observed. Instrumental diagnostic methods sometimes included ultrasound examination of the abdominal organs, chest X-rays, contrast-enhanced gastrointestinal tract X-rays, echocardiography when necessary, and so on.

An example of a contrast-enhanced X-ray of the gastrointestinal tract in an affected dog is shown in Fig. 3. The X-ray contrast medium is visible in the stomach with uneven distribution and delayed evacuation, indicating impaired motor and evacuation function. The loops of the small intestine have an uneven diameter, appear tortuous in places, with no distinct fluid levels and no sharp break in contrast. No signs of mechanical obstruction, intussusception, or foreign bodies were detected. The radiographic picture is characterized by functional (paralytic) ileus, presumably caused by inflammatory and necrotic changes in the intestinal mucosa against the background of a parvovirus infection. No signs of free gas in the abdominal cavity were detected (Fig. 3). Impaired motility and delayed passage of the contrast agent may be a consequence of damage to the intestinal crypt cells, characteristic of parvovirus infection, leading to wall edema, hypomotility, and the development of paralytic ileus. The obtained radiographic data confirm the appropriateness of conservative therapy and rule out the need for surgical intervention at the time of the examination.

Parvovirus enteritis in dogs exhibits marked seasonality, which has been identified as a risk factor in Colorado, USA (summer–fall), in Brazil, Canada, and New Zealand (spring–summer), and in Australia (spring–fall) (Kelman et al., 2020; Oliveira et al., 2018; Jiang, 2018). In our study, the disease was significantly more common in the summer-fall period than in winter ($p < 0.05$) (Fig. 4).

An analysis of the incidence by month revealed two peaks during the year, specifically in October and June (12.5% and 10.8% of cases, respectively). The disease was diagnosed slightly less frequently in September and May (9.9% and 9.0%, respectively). The fewest cases were observed in January and February (4.7% and 5.7%, respectively) (Fig. 5).

According to the literature, the prevalence of parvovirus enteritis throughout the year depends on the climatic conditions of the country where the study was conducted, the breeding season, and the movement of animals to shows and breeding facilities (Lisova et al., 2022). In Ukraine, an increase in the incidence of parvovirus enteritis is generally observed during the spring-summer and summer-fall periods, with a slight decrease in the number of cases in winter. For example, in Poltava, the highest incidence of the disease in 2016–2018 occurred in the fall (36.2% of cases) and the lowest in the winter (16.3%) (Titarenko, Pokhylets and Karasenko, 2021). In Brovary (Kyiv Region), parvovirus

enteritis exhibits a clearly defined seasonal pattern, with dogs being more susceptible during the summer–fall season, and the peak incidence of infected animals was recorded in July at 23.1% (Hrebinichenko et al., 2025). In private and state veterinary clinics in Kyiv, Zhytomyr, Vinnytsia, and Berdychiv, according to data from Radzykhovskiy (2021), parvovirus enteritis was most frequently recorded in the fall (29%), less frequently in the summer (25.7%) and in the spring (24.2%), and the lowest number of affected dogs was recorded in the winter (21.1%). Other authors also noted a similar seasonal pattern in their studies (Kone and Romanova, 2017).

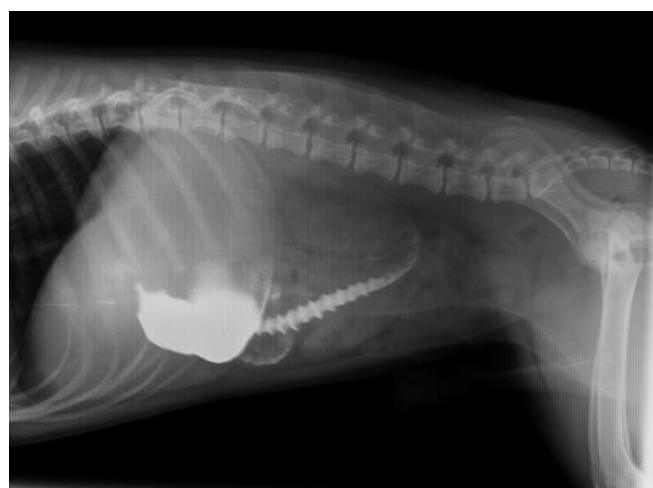


Figure 3. Contrast-enhanced X-ray of the abdominal organs in the examined dog.

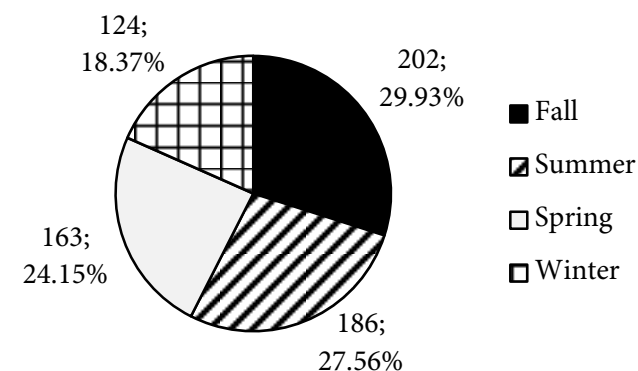


Figure 4. Distribution of positive CPV-2 antigen test results among the dogs examined, by season.

Conclusions. Parvovirus infection is a fairly common condition among dogs seen at the veterinary clinics of the 'Zoolux' network in Kyiv, accounting for 18.1% of examinations.

Despite pronounced seasonality in the summer and fall, which significantly exceeded winter incidence ($p < 0.05$), parvovirus infection in dogs is observed year-round.

In our study, peaks in canine parvovirus incidence were observed in October and June (12.5% and 10.8% of cases, respectively), which is typical for Ukraine.

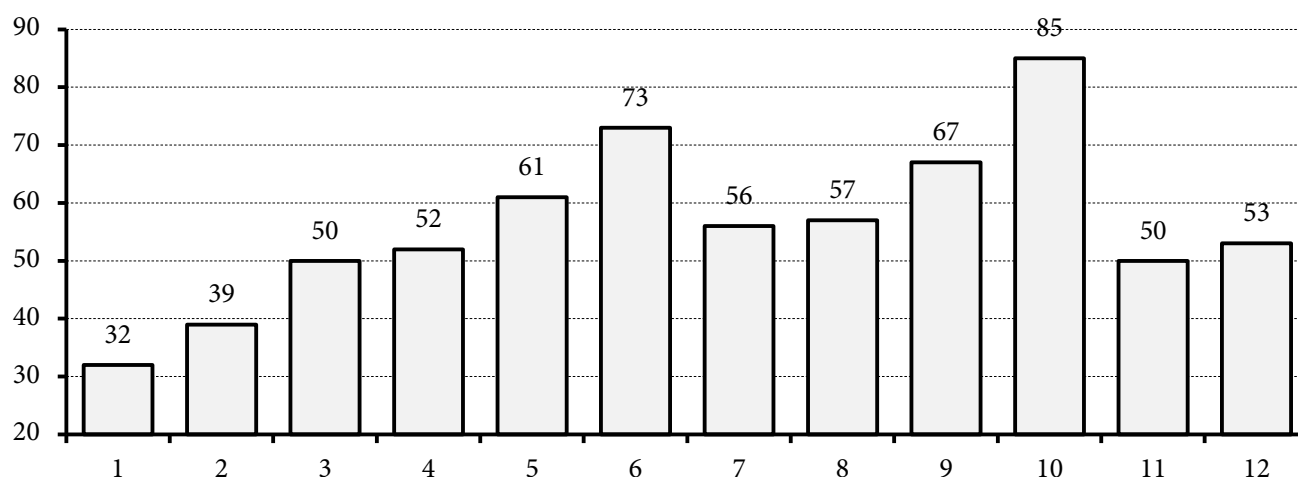


Figure 5. Distribution of positive CPV-2 antigen test results among the dogs examined, by month.

The most common clinical signs of viral enteritis in the dogs examined were lethargy, vomiting, bloody, watery stools with a foul odor, and a refusal to eat or drink. Less frequent signs included cardiovascular and respiratory system involvement.

In clinics, examinations and therapeutic procedures often had to be performed during infusion therapy aimed at rehydrating the animal. This therapy used an infusion stand with an infusion pump or an IV drip.

Diagnostic procedures performed on sick dogs sometimes included ultrasounds of the abdominal organs, chest X-rays, contrast-enhanced X-rays of the

gastrointestinal tract, and echocardiography when necessary.

Prospects for further research. Viral gastroenteritis is a significant challenge in modern veterinary medicine. Further research is needed to develop methods for early and rapid diagnosis of its etiology in dogs. In our opinion, the polymerase chain reaction is the most promising method because it allows for precise identification of the causative agent of the disease. This enables the selection of effective treatment methods for the animal and the prevention of infection spread through the use of specific preventive measures.

References





- Agada, I.-O. C. I., Ameh, J. A., Olabode, O. H. and Echioda-Ogbole, M. (2022) 'Occurrence and distribution patterns of Canine parvoviral enteritis in Abuja, Nigeria', *Journal of Virological Sciences*, 10(2), pp. 1–7. Available at: <https://researchlinks.com/current-issues/Occurrence-Distribution-Patterns-Canine-Parvoviral/29/1/6864>.
- BIOVET.UA (2026) *Rapid Test for the Detection of Canine Parvovirus Antigen, CPV Ag*. *Vet expert*, 10 sp. [Ekspres-test na vyivlennia antyhena parvovirusu sobak, CPV Ag, *Vet expert*, 10 sht.]. Available at: <https://biovet.ua/ua/ekspres-test-na-vyivlennia-antyhena-parvovirusu-sobak-cpv-ag-vet-expert-10-sht>. [in Ukrainian].
- Dong, B., Zhang, G., Zhang, J., Bai, J. and Lin, W. (2020) 'A systematic literature review and meta-analysis of characterization of canine parvoviruses 2 prevalent in mainland China', *Virology Journal*, 17(1), p. 195. doi: 10.1186/s12985-020-01462-3.
- Ford, J., McEndaffer, L., Renshaw, R., Molesan, A. and Kelly, K. (2017) 'Parvovirus infection is associated with myocarditis and myocardial fibrosis in young dogs', *Veterinary Pathology*, 54(6), pp. 964–971. doi: 10.1177/0300985817725387.
- Goralskii, L., Radsikhovskii, N. and Zaika, S. (2018) 'Pathomorphological differential diagnostics of parvovirus and coronavirus entreat in dogs' ['Patomorfologichna dyferentsiina diahnozyka parvovirusnoho ta koronavirusnoho enterytu u sobak'], *Scientific Horizons [Naukovi Horyzonty]*, 21(3), pp. 10–14. doi: 10.33249/2663-2144-2018-66-3-10-14. [in Ukrainian].
- Greene, C. E. and Decaro, N. (2016) 'Canine parvovirus enteritis', *Veterian Key*. Available at: <https://veteriankey.com/canine-viral-enteritis/>.
- Hasan, M. M., Jalal, M. S., Bayzid, M., Sharif, M. A. M. and Masuduzzaman, M. (2017) 'A comparative study on Canine parvovirus infection of dog in Bangladesh and India', *Bangladesh Journal of Veterinary Medicine*, 14(2), pp. 237–241. doi: 10.3329/bjvm.v14i2.31403.
- Hrebinichenko, A., Androshchuk, O., Radzyhovskiy, M., Kovalenko, V., Dyshkant, O., Sokulskiy, I., Dunaievska, O., Ukhovskiy, V., Koshevoy, V. and Mezhenka, N. (2025) 'Epizootological features of the manifestation of Parvovirus infection in dogs' [Epizootologichni osoblyvosti proiavu parvovirusnoi infektsii u sobak], *Scientific and Technical Bulletin of State Scientific Research Control Institute of Veterinary Medical Products and Fodder Additives and Institute of Animal Biology [Naukovo-tekhnichnyi biuleten Derzhavnogo naukovo-doslidnoho kontrolnoho instytutu veterynarykh preparativ ta kormovykh dobavok i Instytutu biolohii tvaryn]*, 26(1), pp. 34–40. doi: 10.36359/scivp.2025-26-1.04. [in Ukrainian].
- Ilchenko, O. O. and Tsarenko, T. M. (2020) 'Epizootic situation, diagnosis and prevention of infectious diseases of dogs in a private veterinary hospital' [Epizootychna sytuatsiia, diahnozyka ta profilaktyka infektsiinykh khvorob sobak v umovakh pryvatnoi veterynarnoi likarni], *Current Problems of Veterinary Medicine: proceedings of international scientific and practical undergraduate conference, Bila Tserkva, 20 November, 2020 [Aktualni problemy veterynarnoi medytsyny: materialy mizhnarodnoi naukovo-praktychnoi konferentsii mahistrantiv, Bila Tserkva, 20 lystopada 2020 roku]*. Bila Tserkva: Bila Tserkva National Agrarian University Available at: <https://rep.btsau.edu.ua/handle/BNAU/6158>. [in Ukrainian].

- Jiang, F. (2018) 'Bioclimatic and altitudinal variables influence the potential distribution of canine parvovirus type 2 worldwide', *Ecology and Evolution*, 8(9), pp. 4534–4543. doi: 10.1002/ece3.3994.
- Kelman, M., Barrs, V. R., Norris, J. M. and Ward, M. P. (2020) 'Socioeconomic, geographic and climatic risk factors for Canine parvovirus infection and euthanasia in Australia', *Preventive Veterinary Medicine*, 174, p. 104816. doi: 10.1016/j.prevetmed.2019.104816.
- Kone, M. S. and Romanova, A. L. (2017) 'The effectiveness of the treatment and prevention of Parvovirus enteritis of dog in conditions of veterinary clinics LLC 'Biocenter' in city Poltava' [Efektyvnist likuvannia ta profilaktyky parvovirusnoho enterytu sobak v umovakh veterynarnykh klinik TOV 'Biotsentr' m. Poltava], *Bulletin of the Poltava State Agrarian Academy [Visnyk Poltavskoi derzhavnoi ahrarnoi akademii]*, (1-2), pp. 123–125. doi: 10.31210/visnyk2017.1-2.24. [in Ukrainian].
- Lisova, V. V., Radzykhovskiy, M. L. and Dyshkant, O. V. (2022) *Parvovirus in Dogs [Parvovirozy v sobak]*. Zhytomyr: Ievro-Volyn. ISBN: 9786177992379. Available at: <https://dglib.nubip.edu.ua/handle/123456789/9454>. [in Ukrainian].
- Lixandru, L.-M. and Ursachi, A.-I. (2020) 'Myocarditis in Canine parvovirus infections', *Romanian Journal of Veterinary Medicine and Pharmacology*, 5(21), pp. 12–26.
- Mazzaferro, E. M. (2020) 'Update on Canine parvoviral enteritis', *Veterinary Clinics of North America: Small Animal Practice*, 50(6), pp. 1307–1325. doi: 10.1016/j.cvsm.2020.07.008.
- Naveenkumar, V., Bharathi, M. V., Kannan, P., Selvaraju, G., Nag, B. S. P. and Vijayarani, K. (2025) 'Climatic risk factors and predictive modelling of Canine parvoviral enteritis outbreaks: An eight-year study from Southern India', *Preventive Veterinary Medicine*, 242, p. 106573. doi: 10.1016/j.prevetmed.2025.106573.
- Ngu Ngwa, V., Bayanga, H. G. E. and Kouamo, J. (2020) 'Epidemiology of Canine parvovirus enteritis in dogs of the Metropolitan City of Yaounde, Cameroon', *Journal of Animal and Veterinary Advances*, 19(10), pp. 129–136. Available at: <https://www.makhillpublications.co/public/index.php/view-article/1680-5593/javaa.2020.129.136>.
- Ogbu, K., Chukwudi, I., Ijomanta, O., Agwu, E. and Chinonye, C. (2016) 'Prevalence of Canine parvovirus in Jos North and South Local Government Areas of Plateau State', *British Microbiology Research Journal*, 13(2), pp. 1–5. doi: 10.9734/bmrj/2016/22813.
- Oliveira, P. S. B., Cargnelutti, J. F., Masuda, E. K., Figuera, R. A., Kommers, G. D., da Silva, M. C., Weiblen, R. and Flores, E. F. (2018) 'Epidemiological, clinical and pathological features of Canine parvovirus 2c infection in dogs from southern Brazil', *Pesquisa Veterinária Brasileira*, 38(1), pp. 113–118. doi: 10.1590/1678-5150-pvb-5122.
- Prosolenko, S. A. (2023) *Parvovirus Enteritis in Dogs and Methods of Its Treatment in the Conditions of the Private Veterinary Clinic 'Zoolyuks' of Kyiv [Parvovirusnyi enteryt sobak ta metody yoho likuvannia v umovakh pryvatnoi vet. kliniky 'Zoolyuks' m. Kyiv]*. Master's thesis. Kharkiv: State Biotechnological University. [in Ukrainian].
- Radzykhovskiy, M. L. (2021) *Pathomorphology, Diagnosis, Treatment and Prevention of Enteritis of Viral Etiology in Dogs [Patomorfolohiia, diahnostyka, likuvannia ta profilaktyka enterytiv virusnoi etiologii u sobak]*. The dissertation thesis for the scientific degree of the doctor of veterinary sciences. Zhytomyr: Polissia National University. Available at: <https://nrat.ukrintei.ua/searchdoc/0521U100370>. [in Ukrainian].
- Sato-Takada, K., Flemming, A. M., Voordouw, M. J. and Carr, A. P. (2022) 'Parvovirus enteritis and other risk factors associated with persistent gastrointestinal signs in dogs later in life: A retrospective cohort study', *BMC Veterinary Research*, 18(1), p. 96. doi: 10.1186/s12917-022-03187-7.
- Streletskiy, O. S. (2022) *Features of Diagnostics and Treatment and Preventive Measures for Viral Enteritis in Dogs in the Conditions of the Veterinary Center 'Bio-Vet' of the Individual Entrepreneur Romashchenko O. P. of the Industrial district of the city of Dnipro [Osoblyvosti diahnostyky ta likuvalno-profilaktychni zakhody za virusnykh enterytiv sobak v umovakh veterynarnoho tsentru 'Bio-Vet' fizychnoi osoby-pidpriemtsia Romashchenko O. P. Industrialnoho raionu mista Dnipro]*. Master's thesis. Dnipro: Dnipro State Agrarian and Economic University. Available at: <https://dspace.dsau.dp.ua/items/bfc49546-4fcb-4315-abf9-ed9dbf8a7d70>. [in Ukrainian].
- Tagorti, G. (2018) 'Prevalence of Canine parvovirus infection in Grand Tunis, Tunisia', *Journal of Advanced Veterinary and Animal Research*, 5(1), pp. 93–97. doi: 10.5455/javar.2018.e251.
- Titarenko, O. V., Pokhylets, K. S. and Karasenko, A. Yu. (2021) 'Diagnostics, treatment and prevention of canine parvovirus enteritis in the clinic 'Veterinary VIP-service' in the city of Poltava' [Diahnostyka, likuvannia ta profilaktyka parvovirusnoho enterytu sobak u klinitsi 'Veterinary VIP-Service' m. Poltava], *Bulletin of Poltava State Agrarian Academy [Visnyk Poltavskoi derzhavnoi ahrarnoi akademii]*, (1), pp. 226–233. doi: 10.31210/visnyk2021.01.28. [in Ukrainian].
- Van Emden, H. F. (2019) *Statistics for Terrified Biologists*. 2nd ed. Hoboken, NJ: John Wiley & Sons. ISBN 9781119563679.
- Zamoshnikov, V. O. (2024a) 'Investigation of diagnostic and correction methods for Cardiorenal syndrome in dogs' [Doslidzhennia metodiv diahnostyky ta korektsii kardiorenalnoho syndromu u sobak], *Veterinary Medicine [Veterynarna medytsyna]*, 110, pp. 235–241. doi: 10.36016/vm-2024-110-37. [in Ukrainian].
- Zamoshnikov, V. O. (2024b) 'A comprehensive approach to the treatment of Cardiorenal syndrome in dogs: From diagnosis to therapy' ['Kompleksnyi pidkhid do likuvannia kardiorenalnoho syndromu u sobak: vid diahnostyky do terapii'], *Agrarian Bulletin of the Black Sea Littoral [Ahrarnyi visnyk Prychornomia]*, 112, pp. 39–48. doi: 10.37000/abbsl.2024.112.07. [in Ukrainian].

Received 23.03.2026

Accepted 05.05.2026

Published 12.05.2026

2026 © Zamoshnikov V. O.  0009-0009-5603-3075, Borovkov S. B.  0000-0003-3021-2410,Yakymchuk I. M.  0009-0001-7617-9153, Sytiuk M. P.  0000-0002-7492-9256

This is an open access article under the terms of the Creative Commons Attribution-NonCommercial-NoDerivs License, which permits use and distribution in any medium, provided the original work is properly cited, the use is non-commercial and no modifications or adaptations are made